

XXV CONGRESO DE LA SEAP ZARAGOZA Mayo 2011

Club de Patología Endocrina

Dra. Pilar Fernández Seara.

Dr. Paco Monzón.

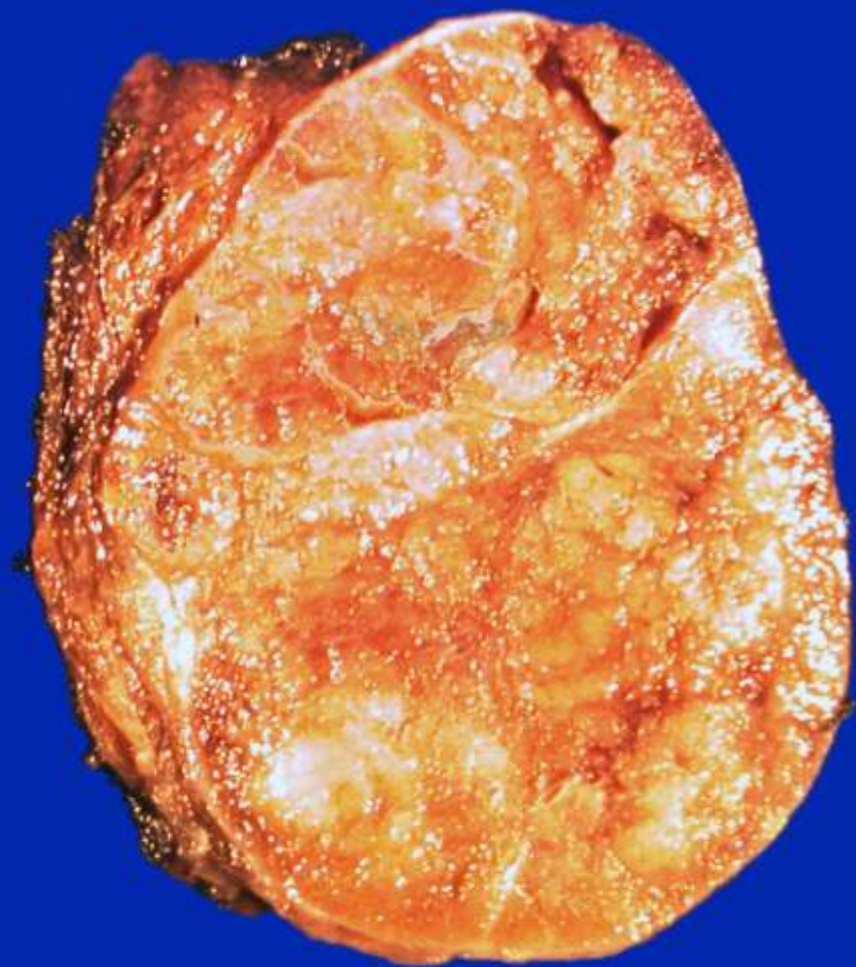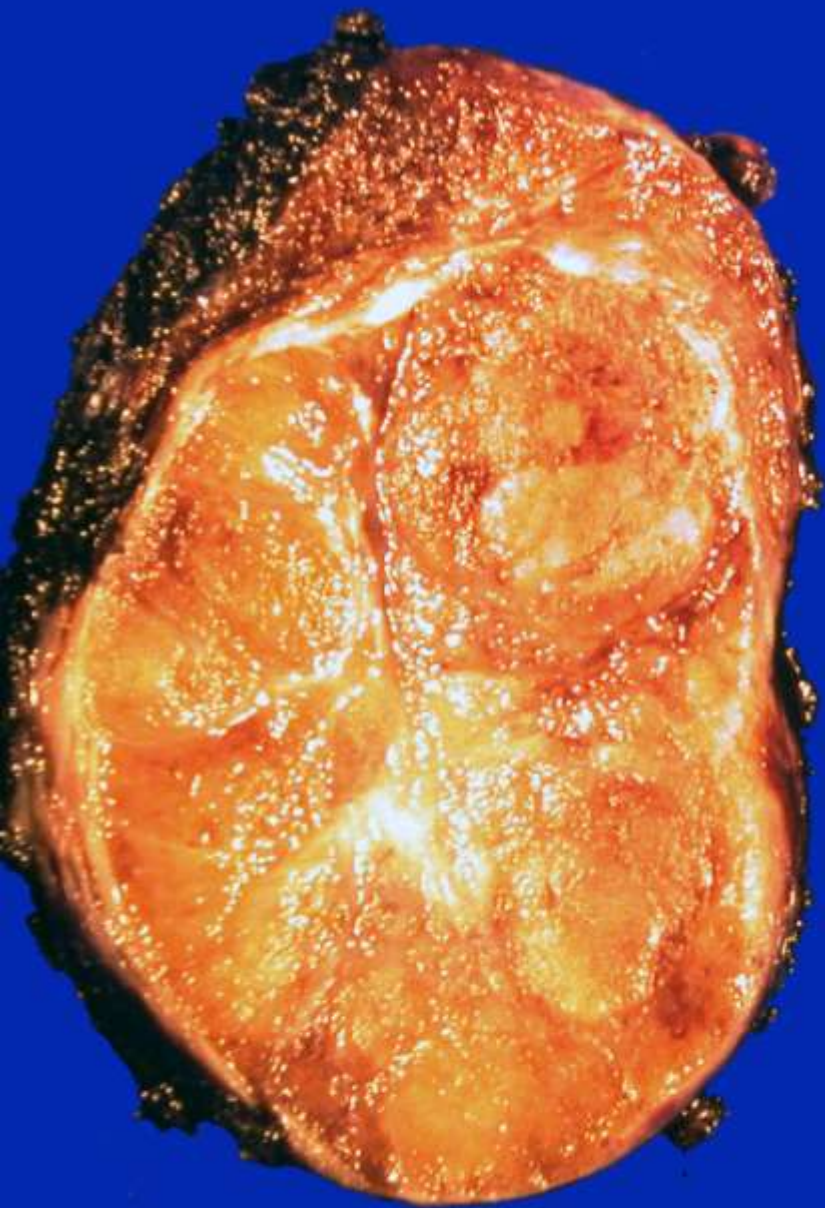
HISTORIA CLINICA

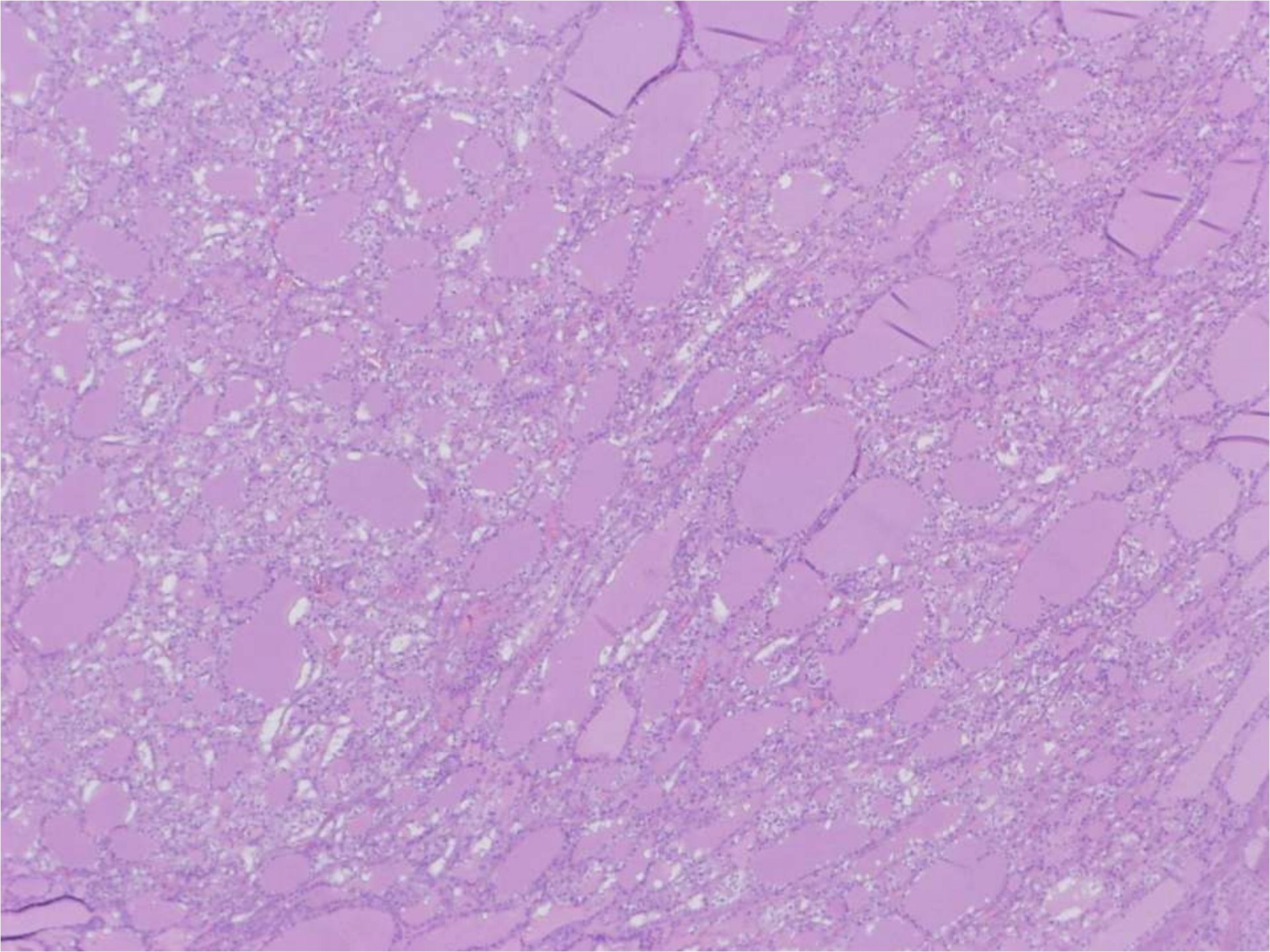
Mujer 66 años.

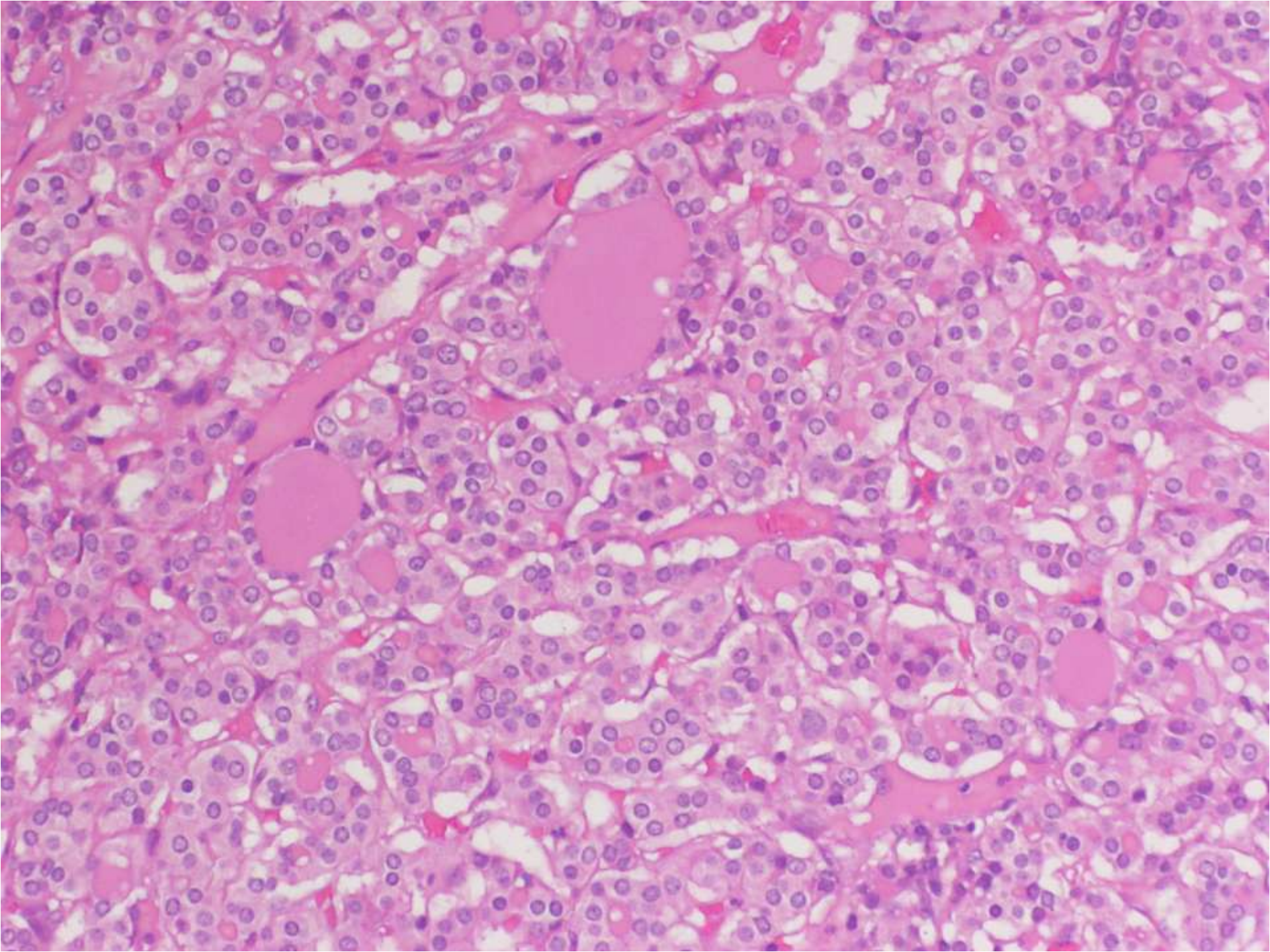
1997 Hemitiroidectomía derecha. Diagnóstico: adenoma folicular hipercelular con patrón insular

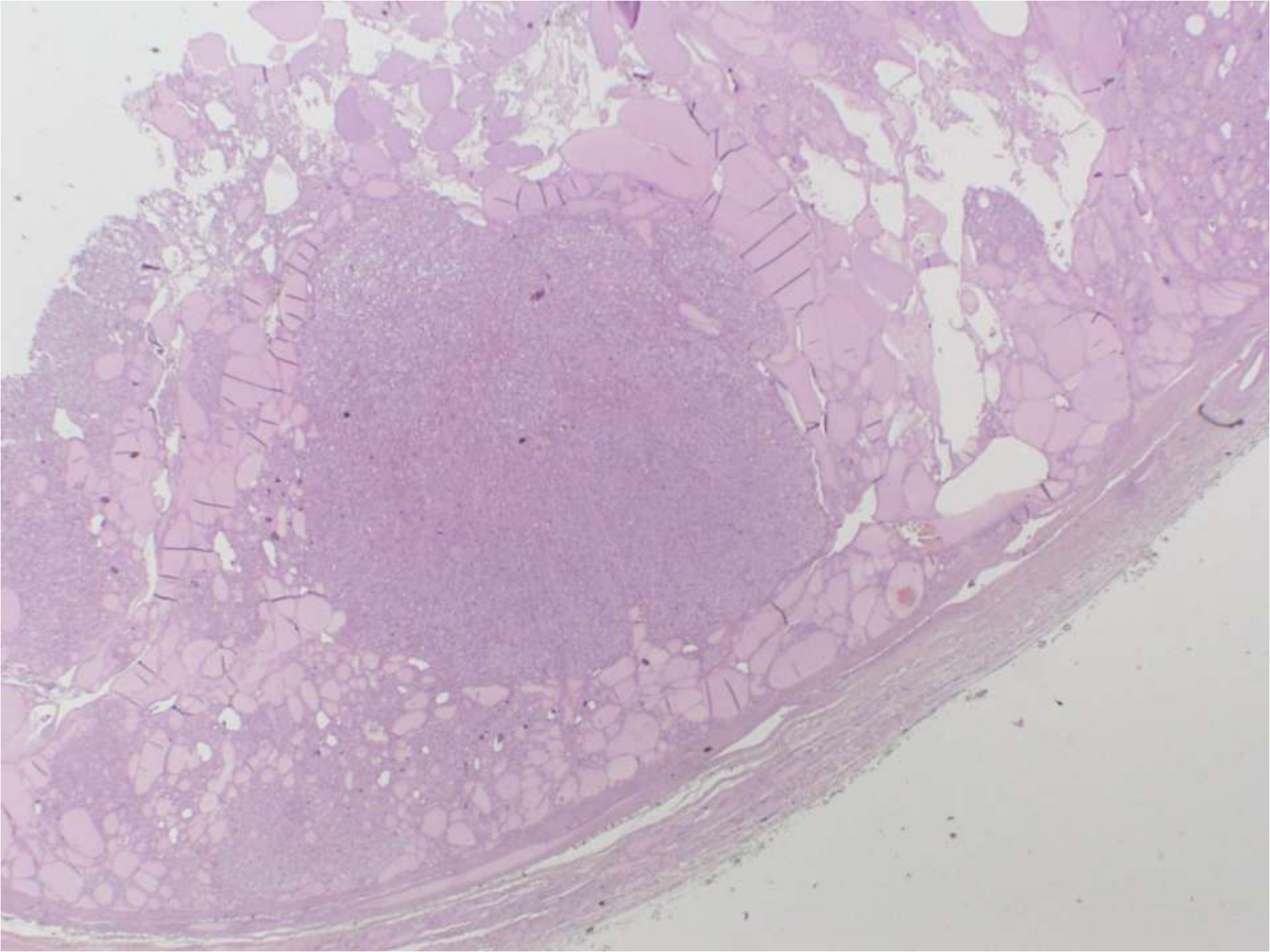
2009 bultoma malar izquierdo. PAAF: compatible con metástasis de carcinoma tiroideo, probable carcinoma pobremente diferenciado.

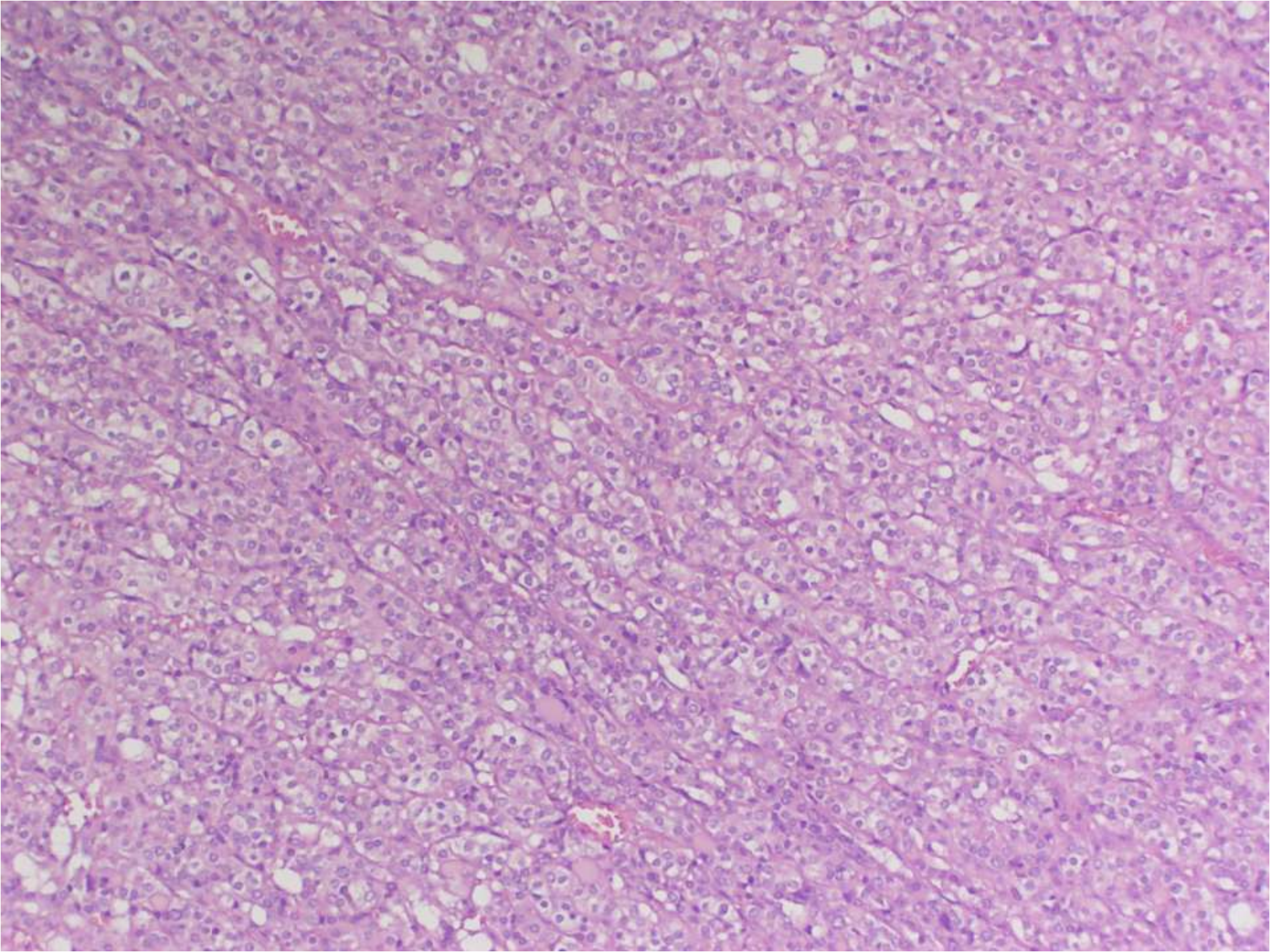
Intervención quirúrgica: resección de lesión malar y se completa tiroidectomía.

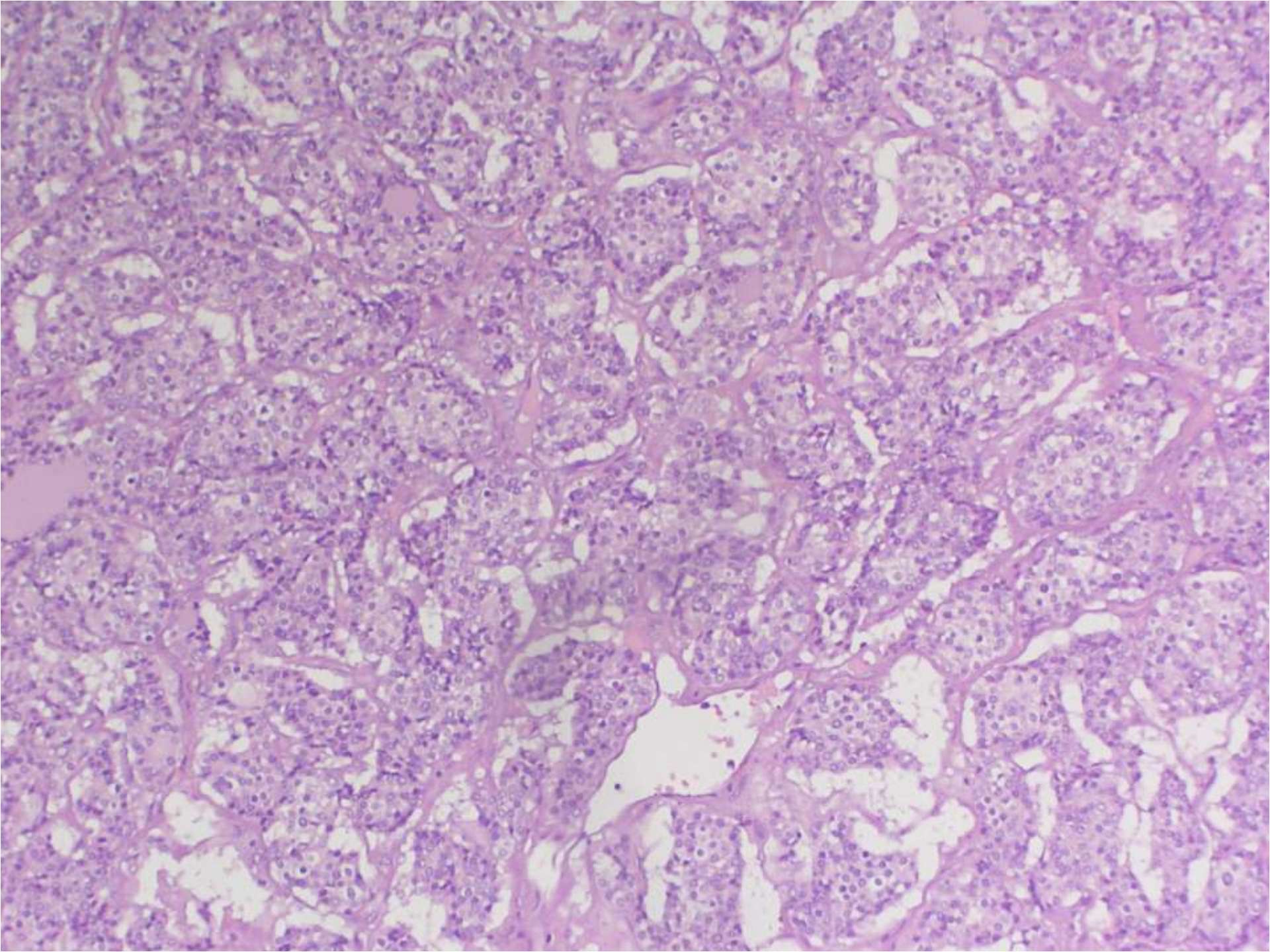


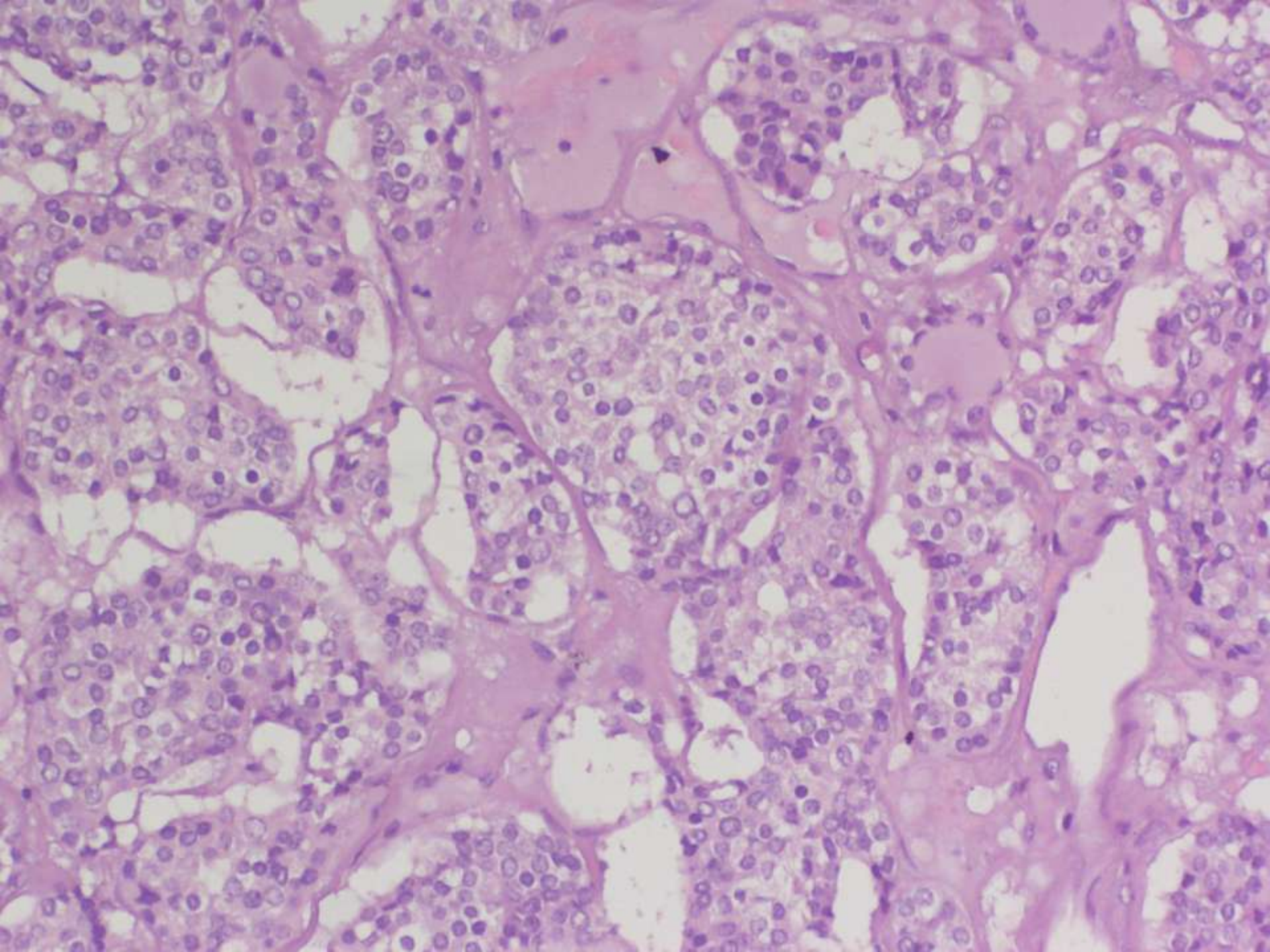


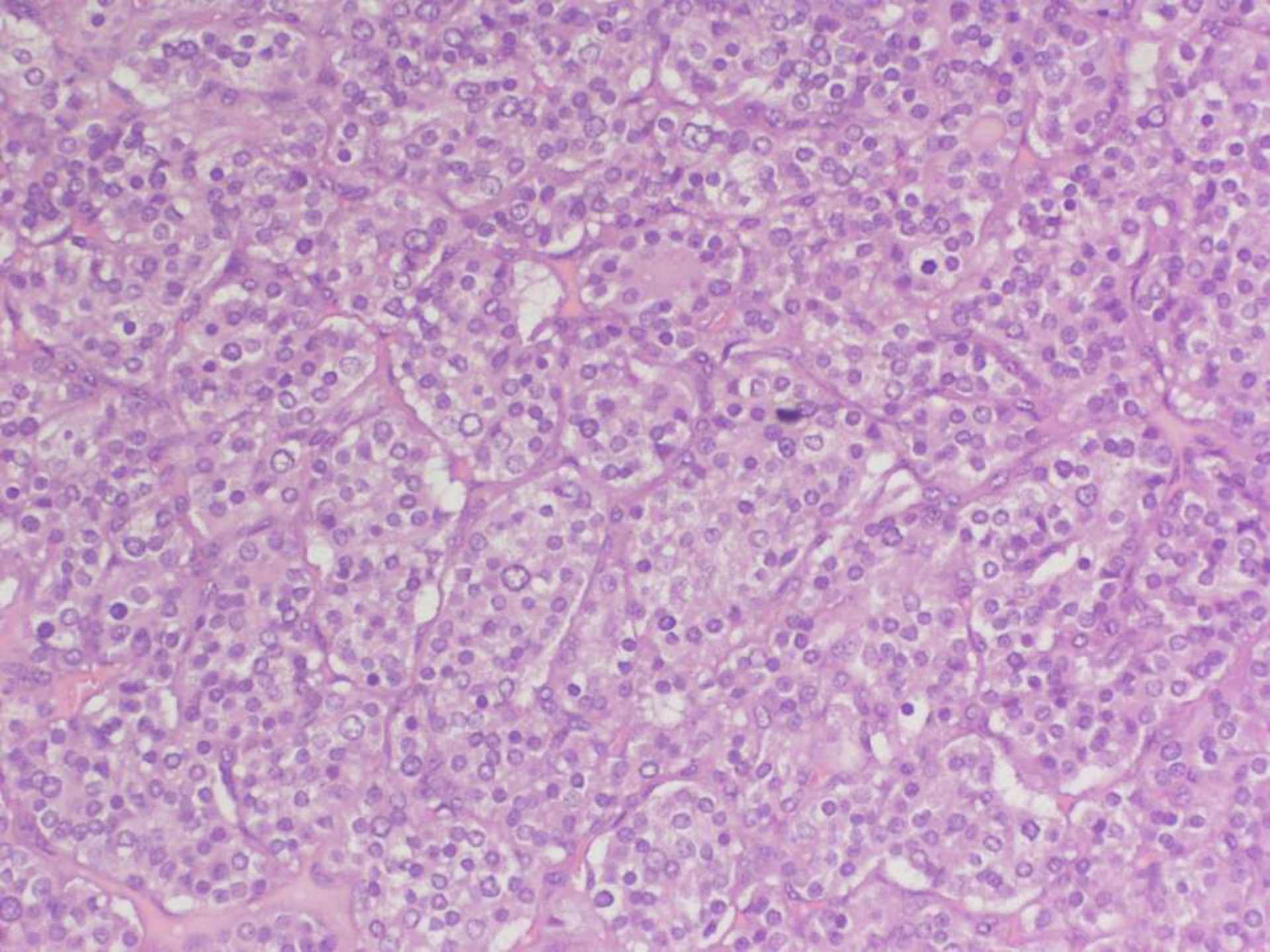


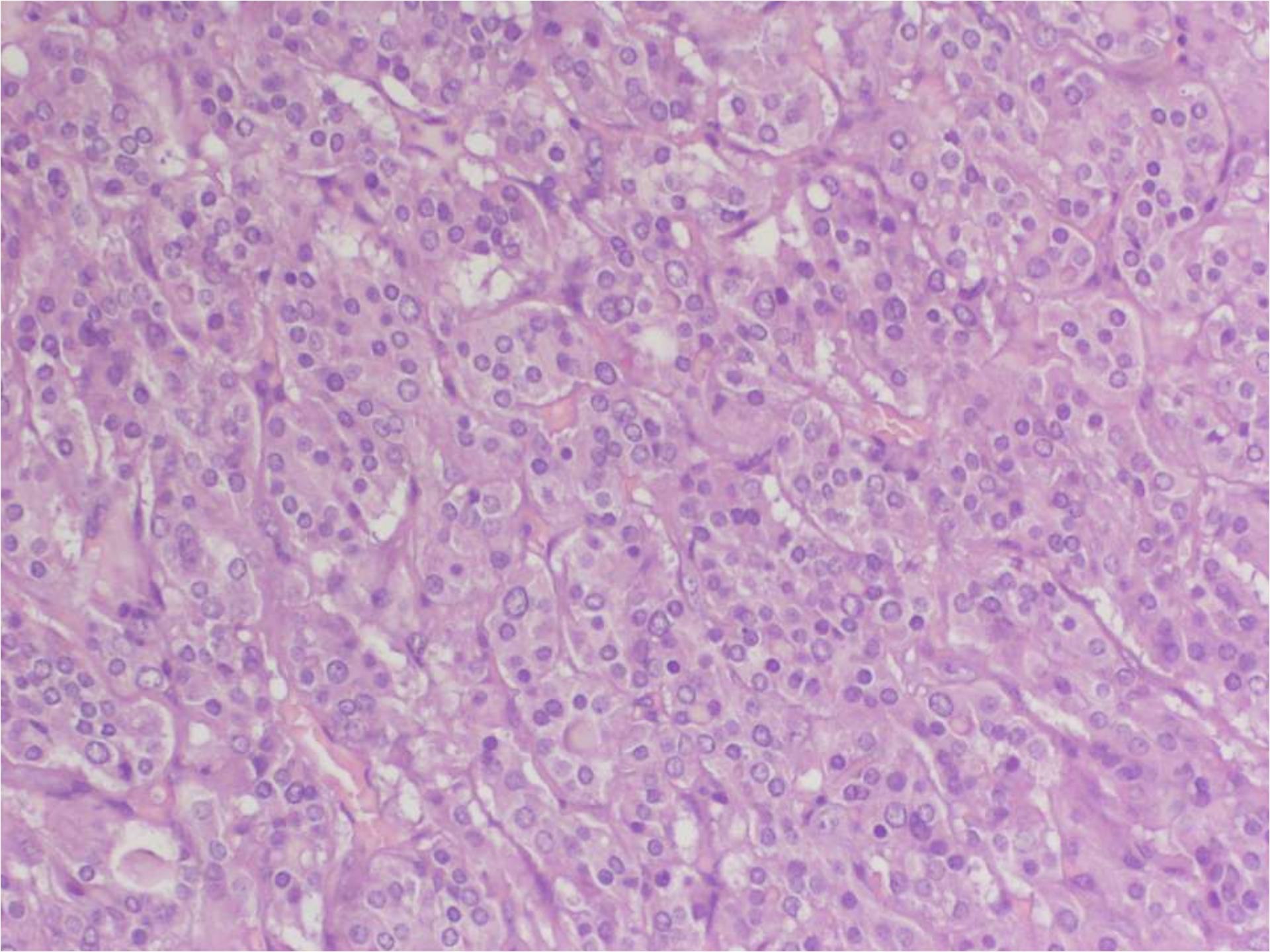


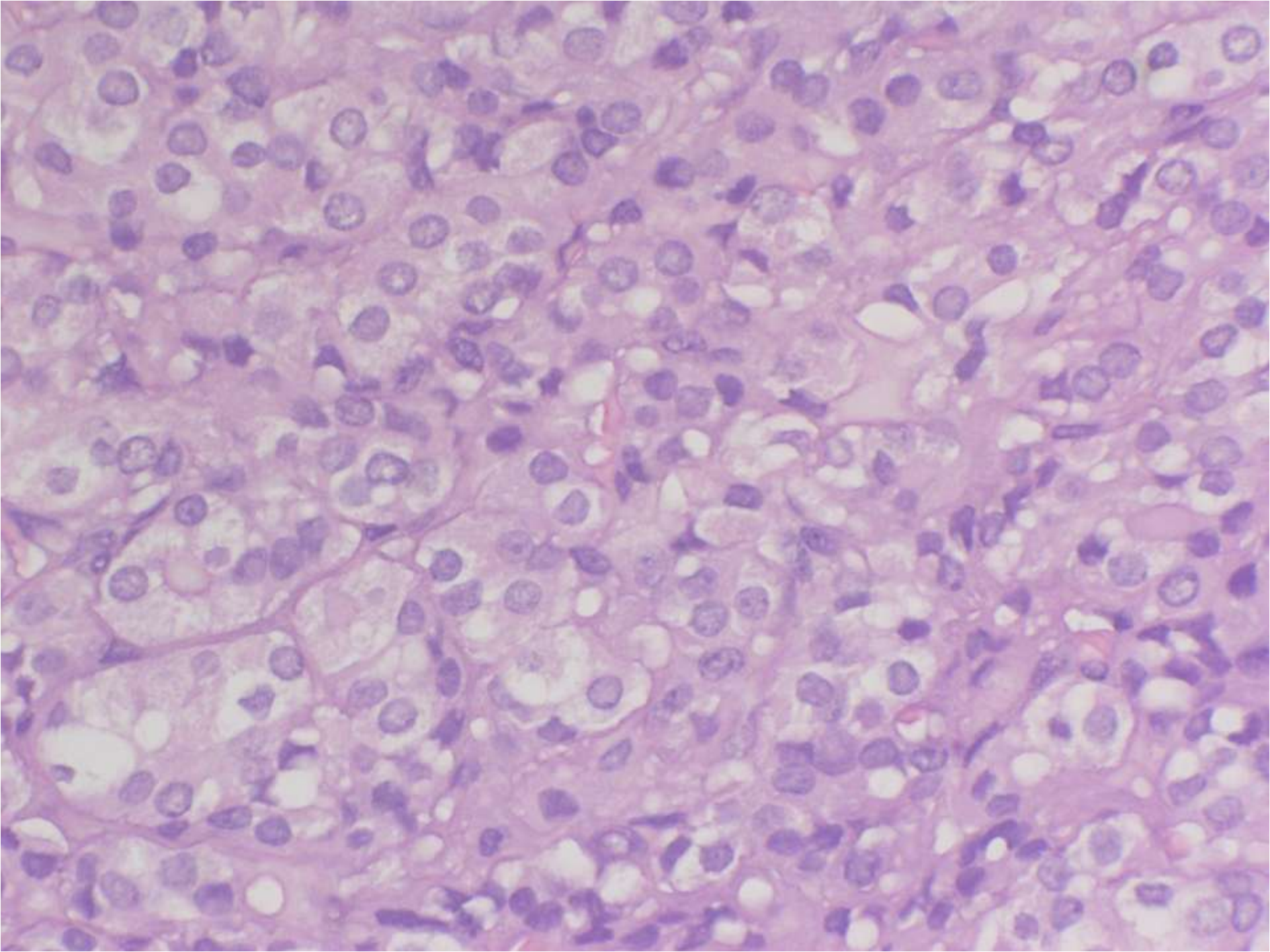


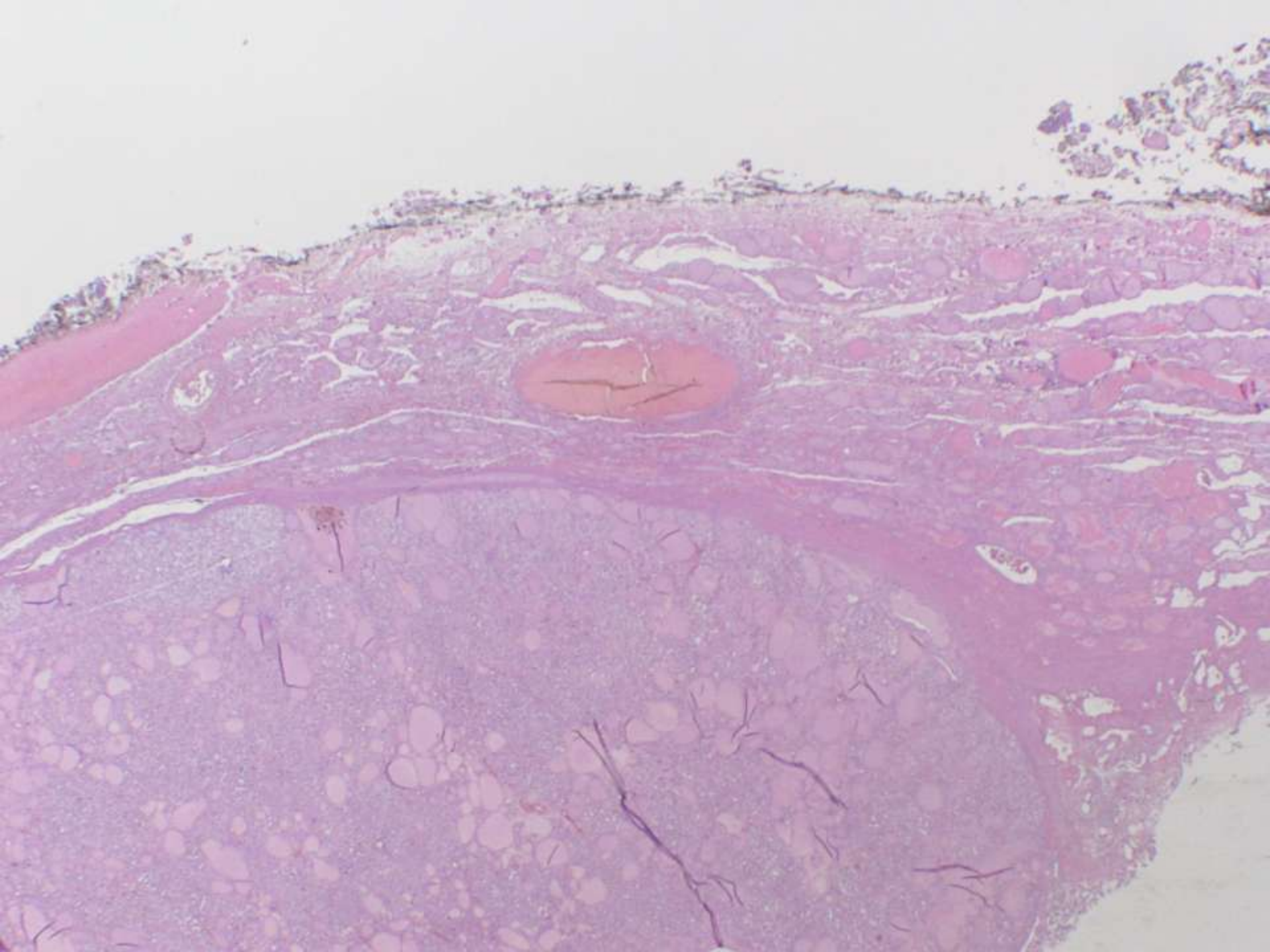


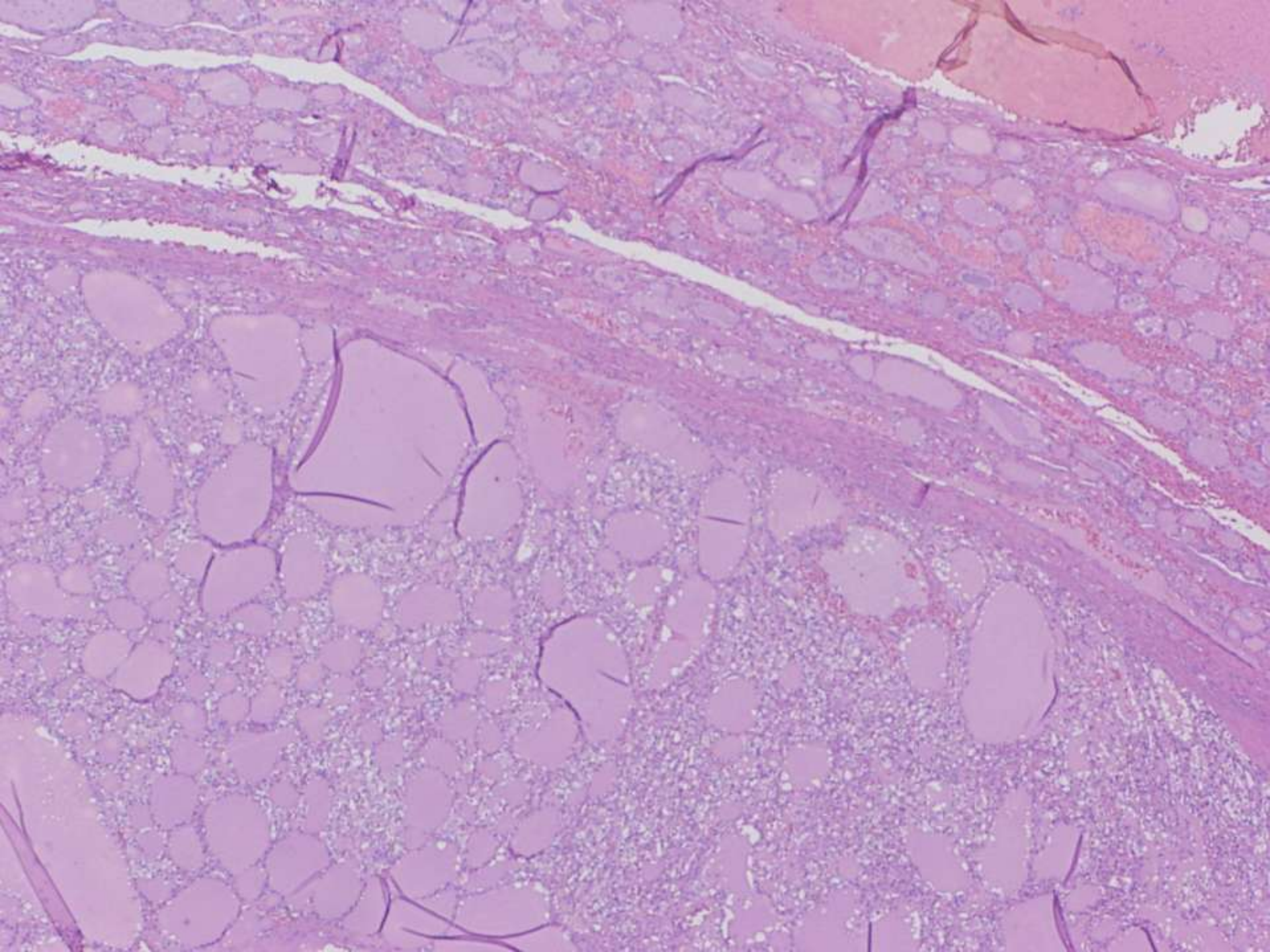












DIAGNOSTICO

**ADENOMA FOLICULAR
HIPERCELULAR CON PATRON
INSULAR**

Signa 1.5T SYS#GEMSO
x: 20741
e: 2
m: 8
Cor A68.8

GARC

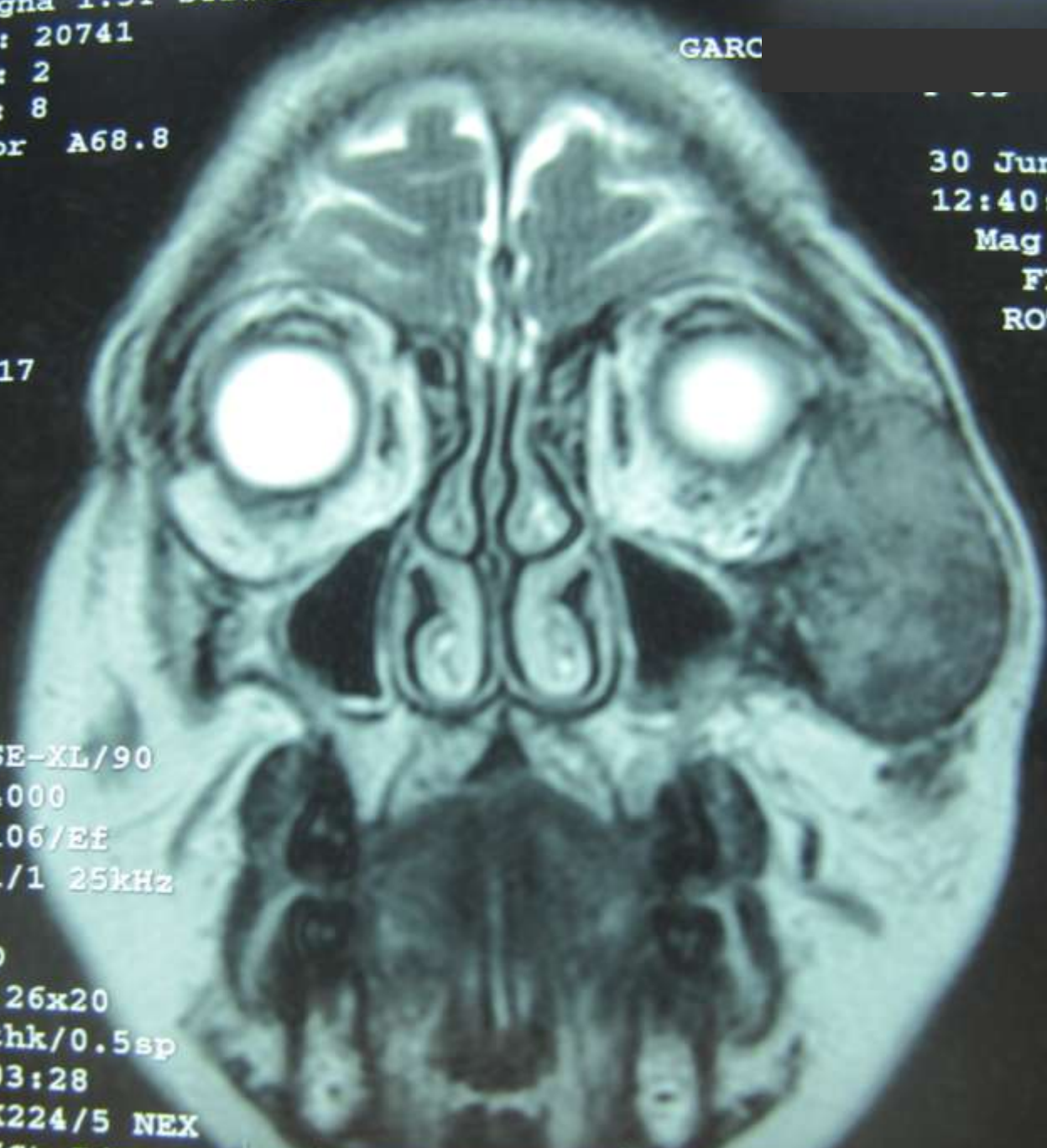AR
41

30 Jun 2008
12:40:00 PM
Mag = 1.5
FL:
ROT:

:17

FSE-XL/90
:4000
:106/Ef
:1/1 25kHz

AD
7:26x20
0thk/0.5sp
/03:28
5X224/5 NEX
E/St:I/VB/Z1024



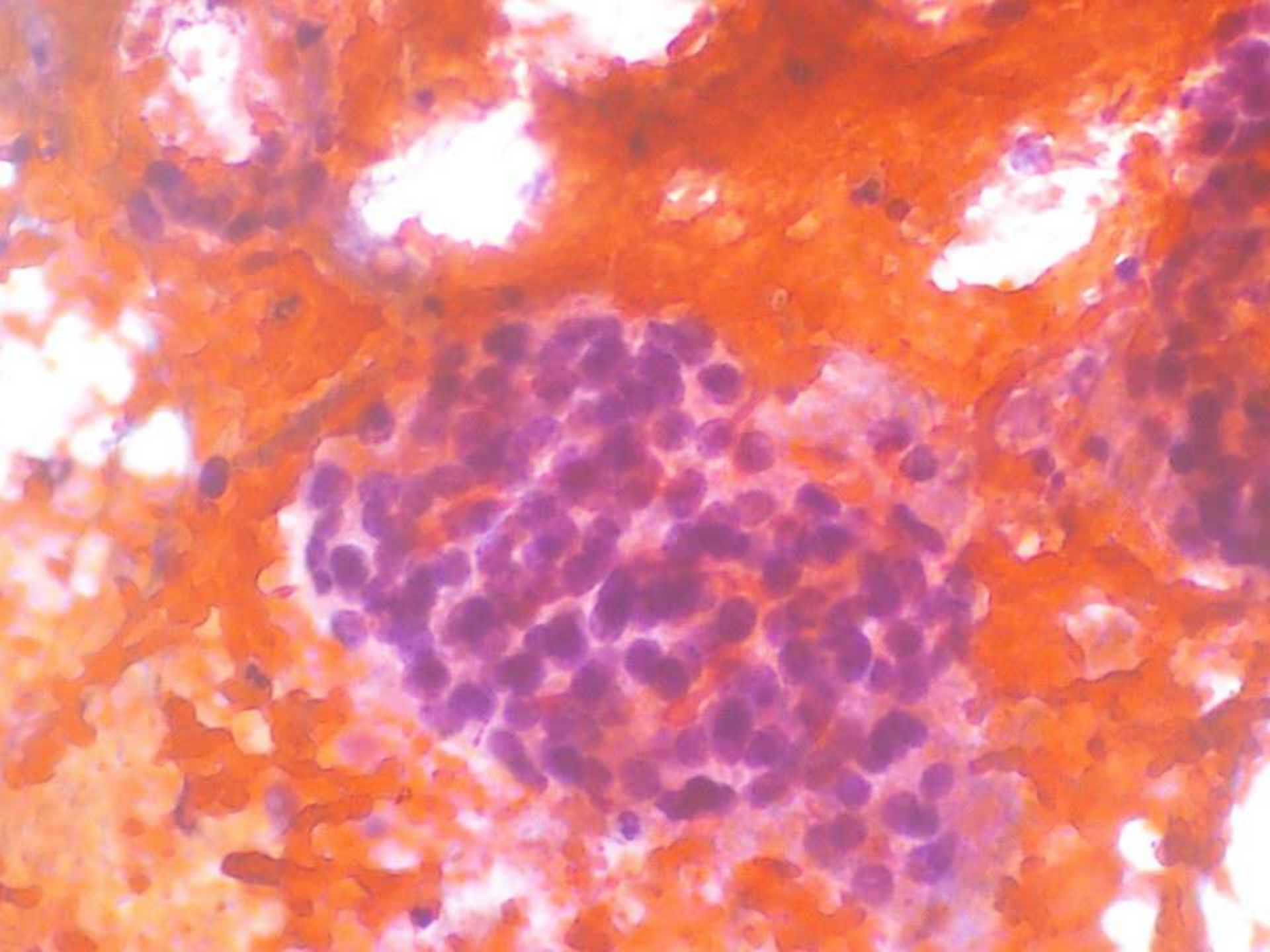
IA

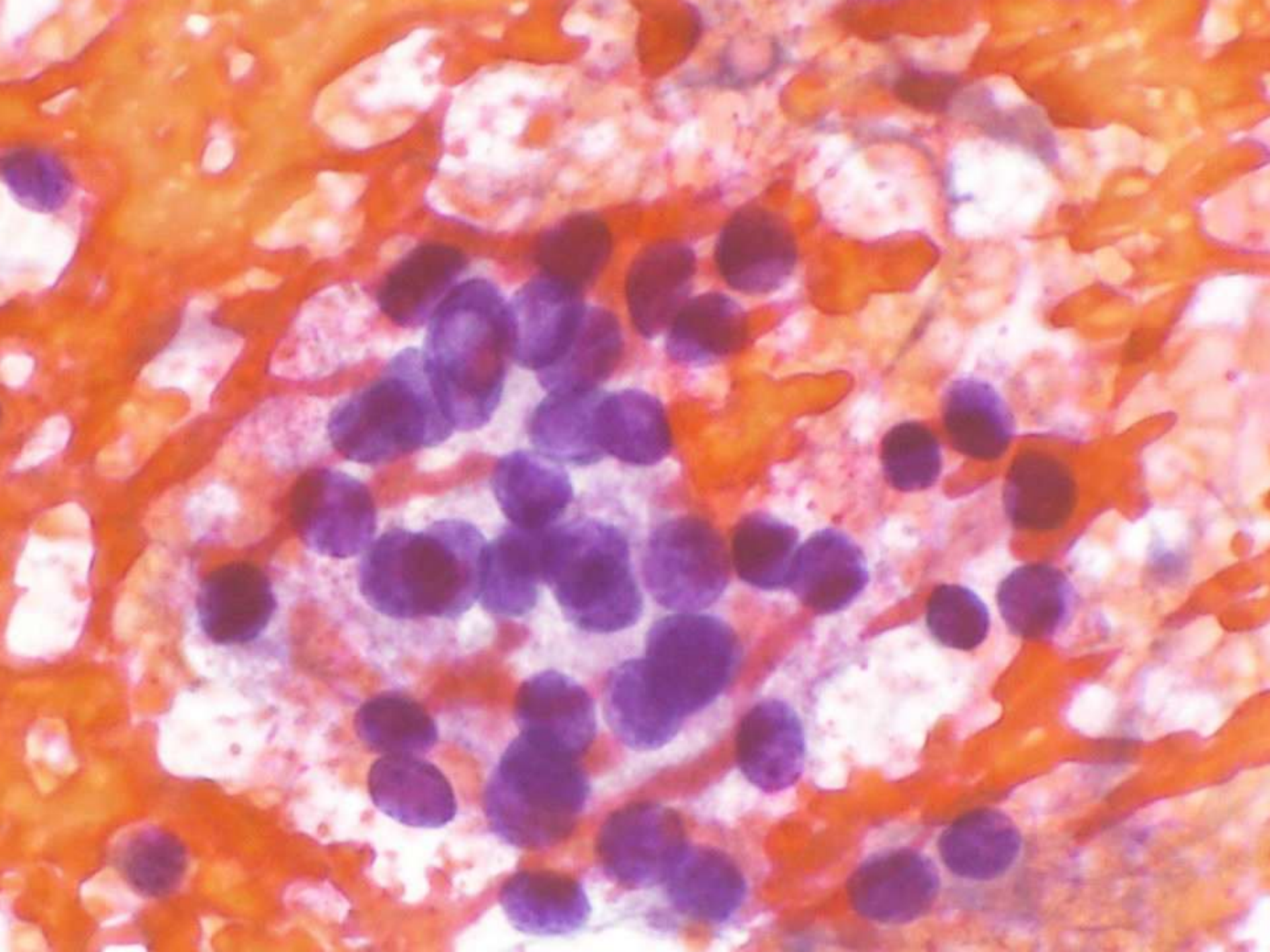
W =

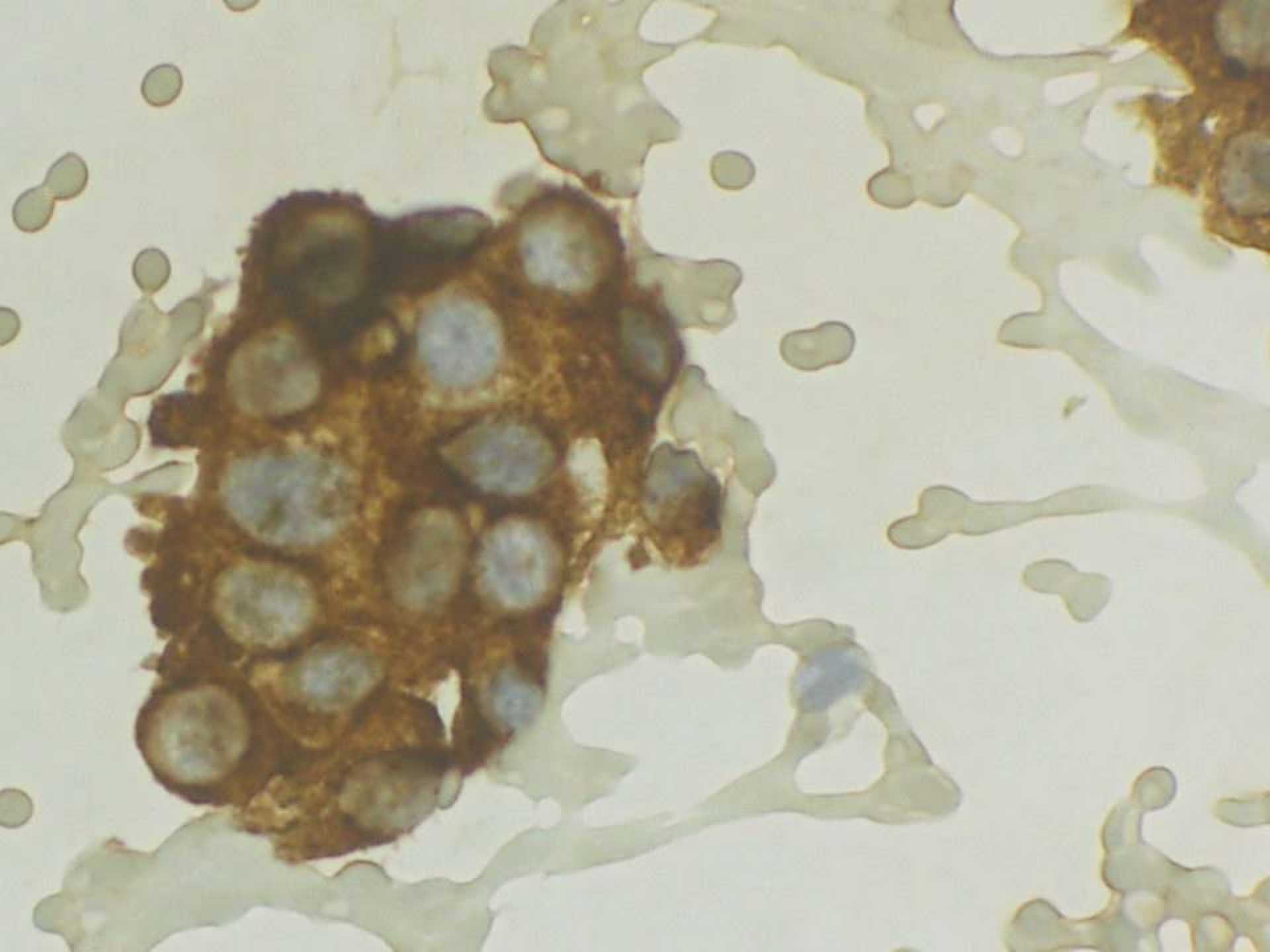
910

L =

39

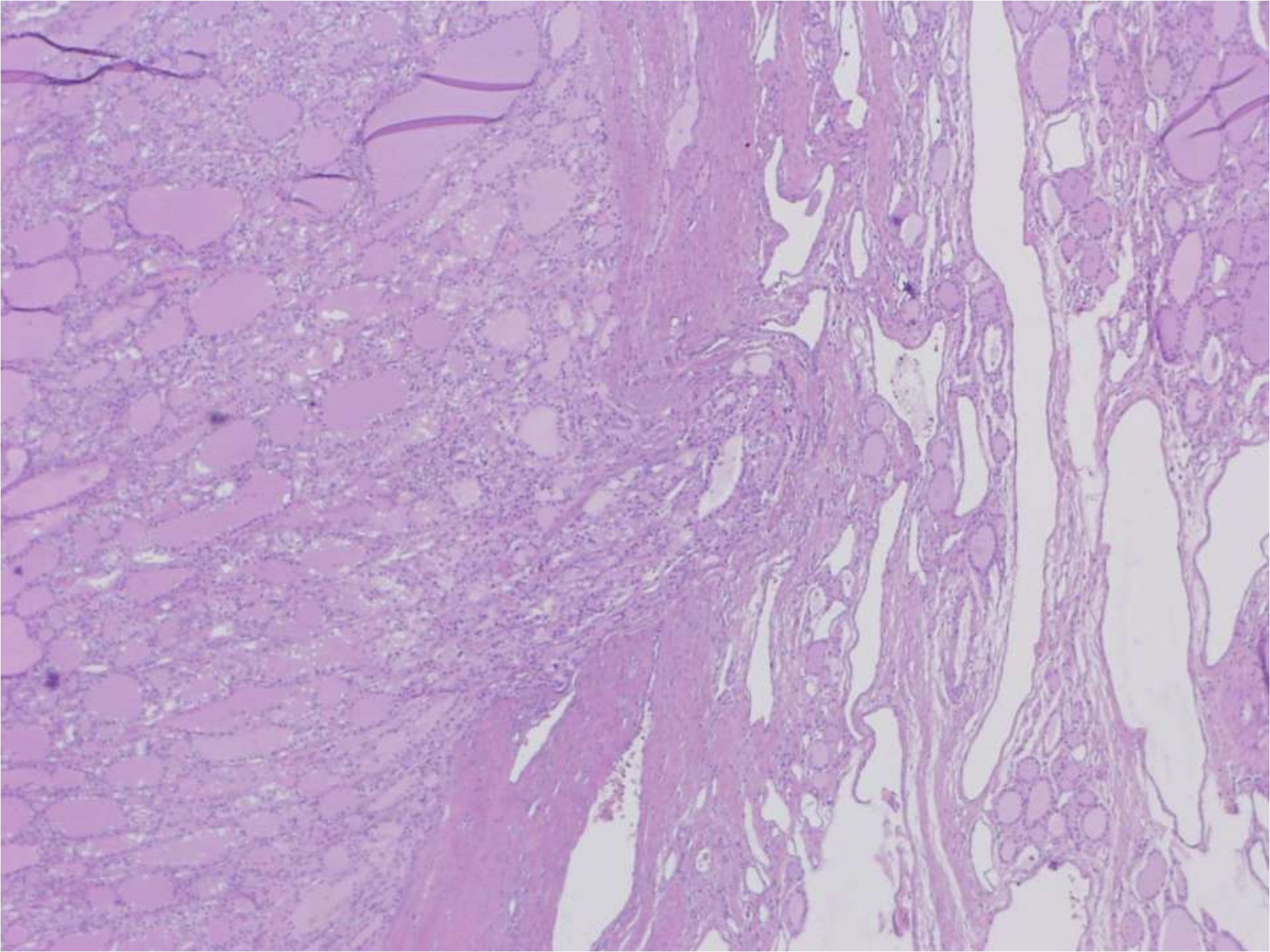


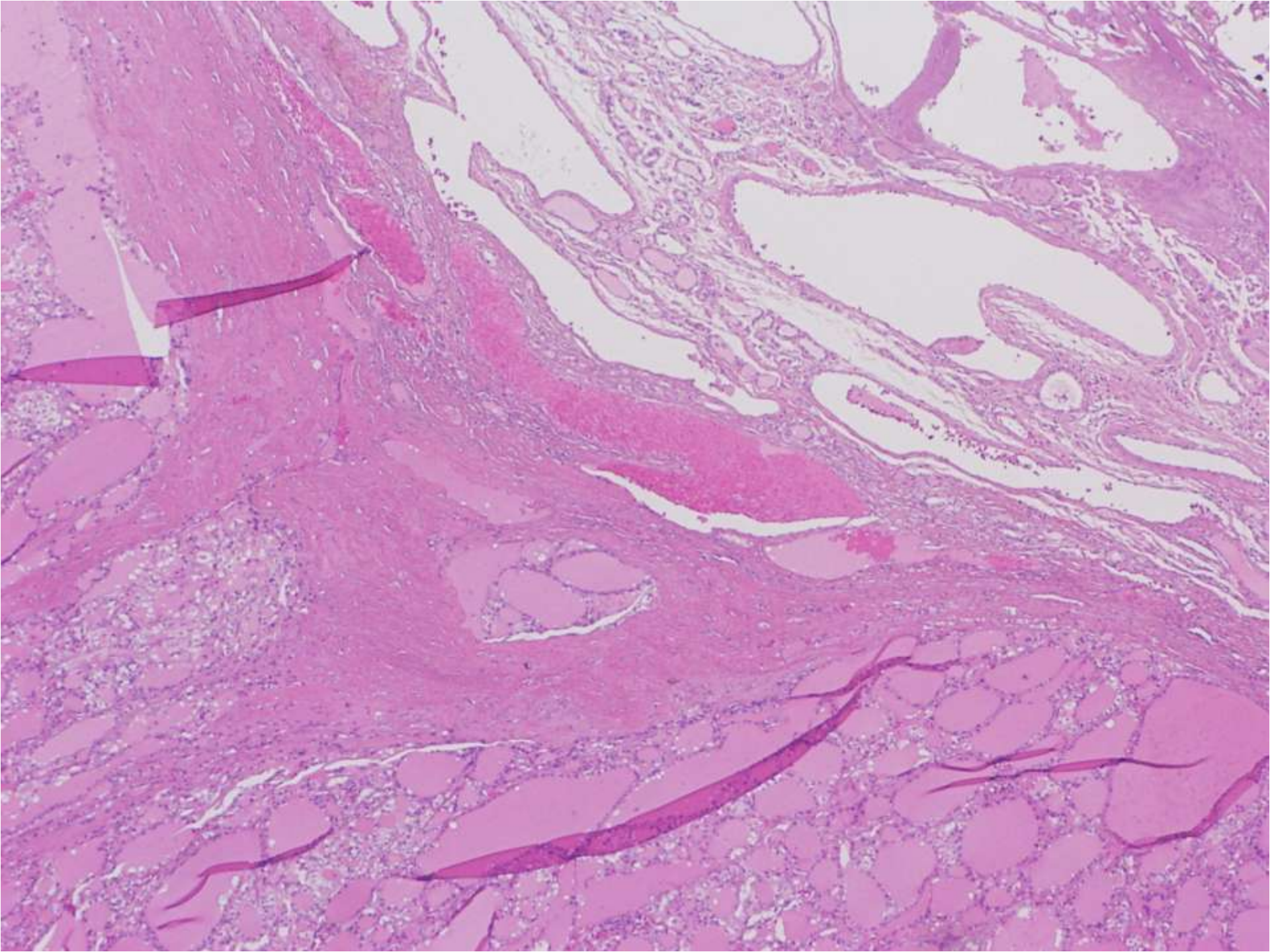


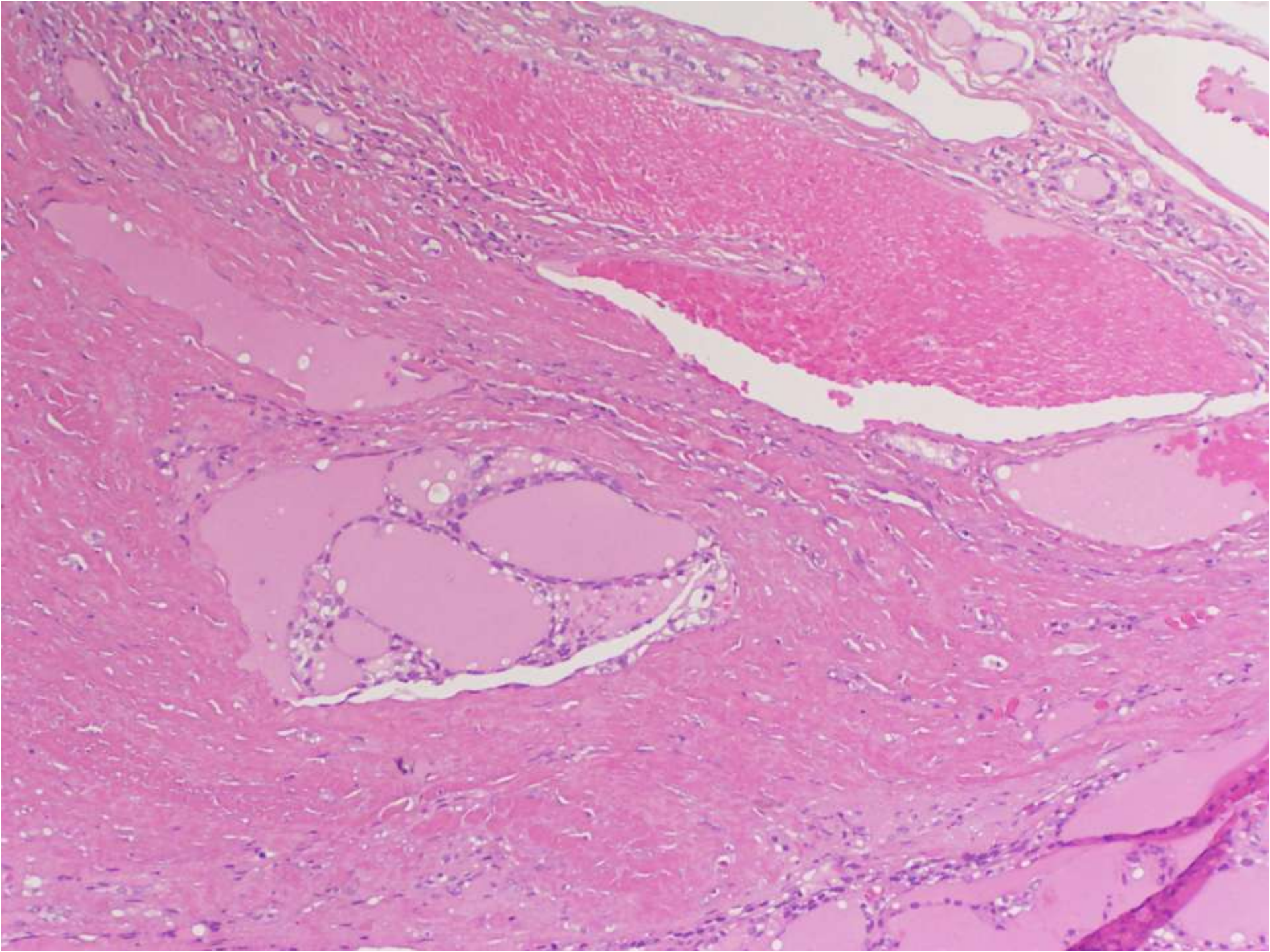


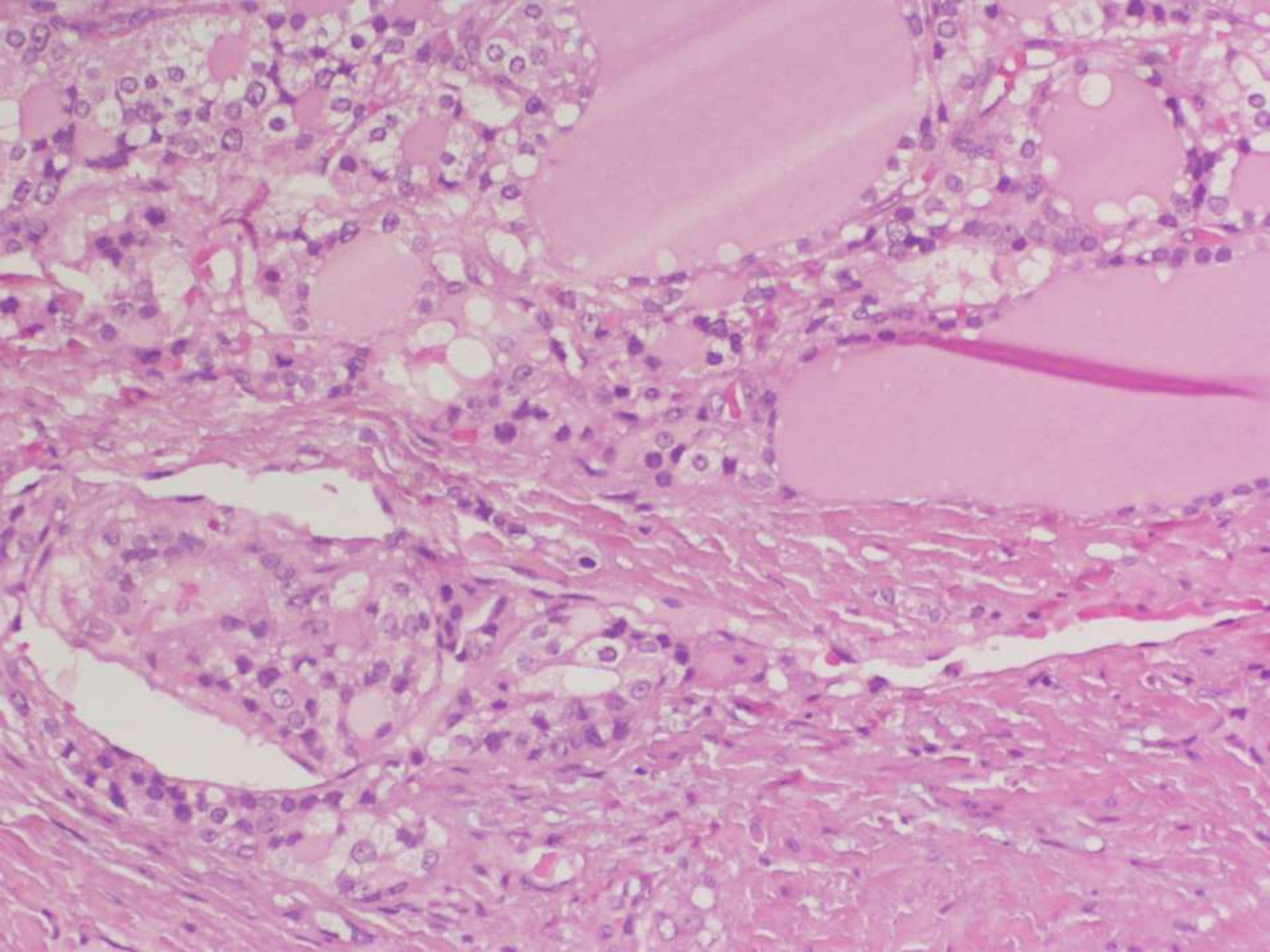
DIAGNOSTICO PAAF

Compatible con metástasis de carcinoma de tiroides probable
Carcinoma pobremente diferenciado.



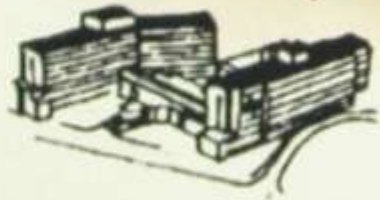





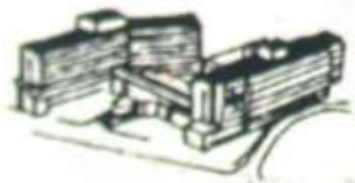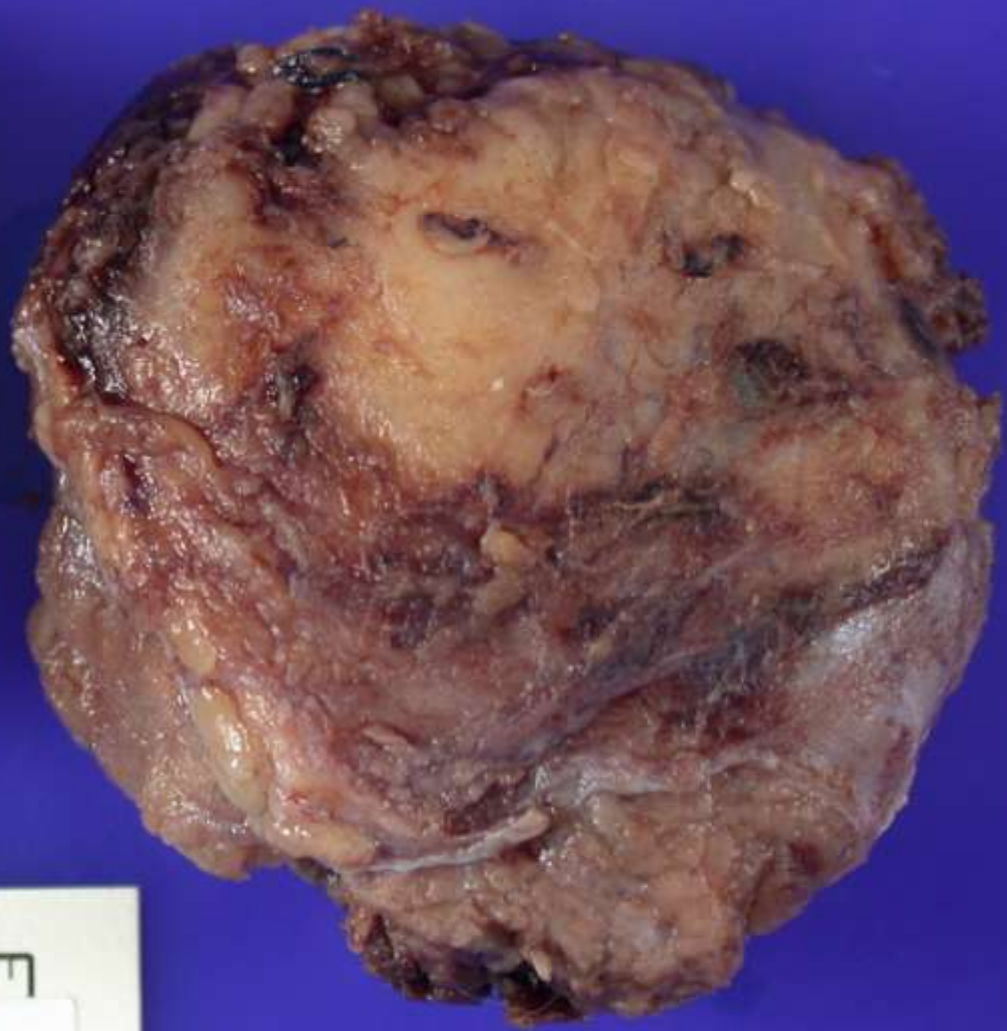
DIAGNOSTICO

CARCINOMA FOLICULAR
MINIMAMENTE INVASIVO
con un 30% de carcinoma
pobrementemente diferenciado



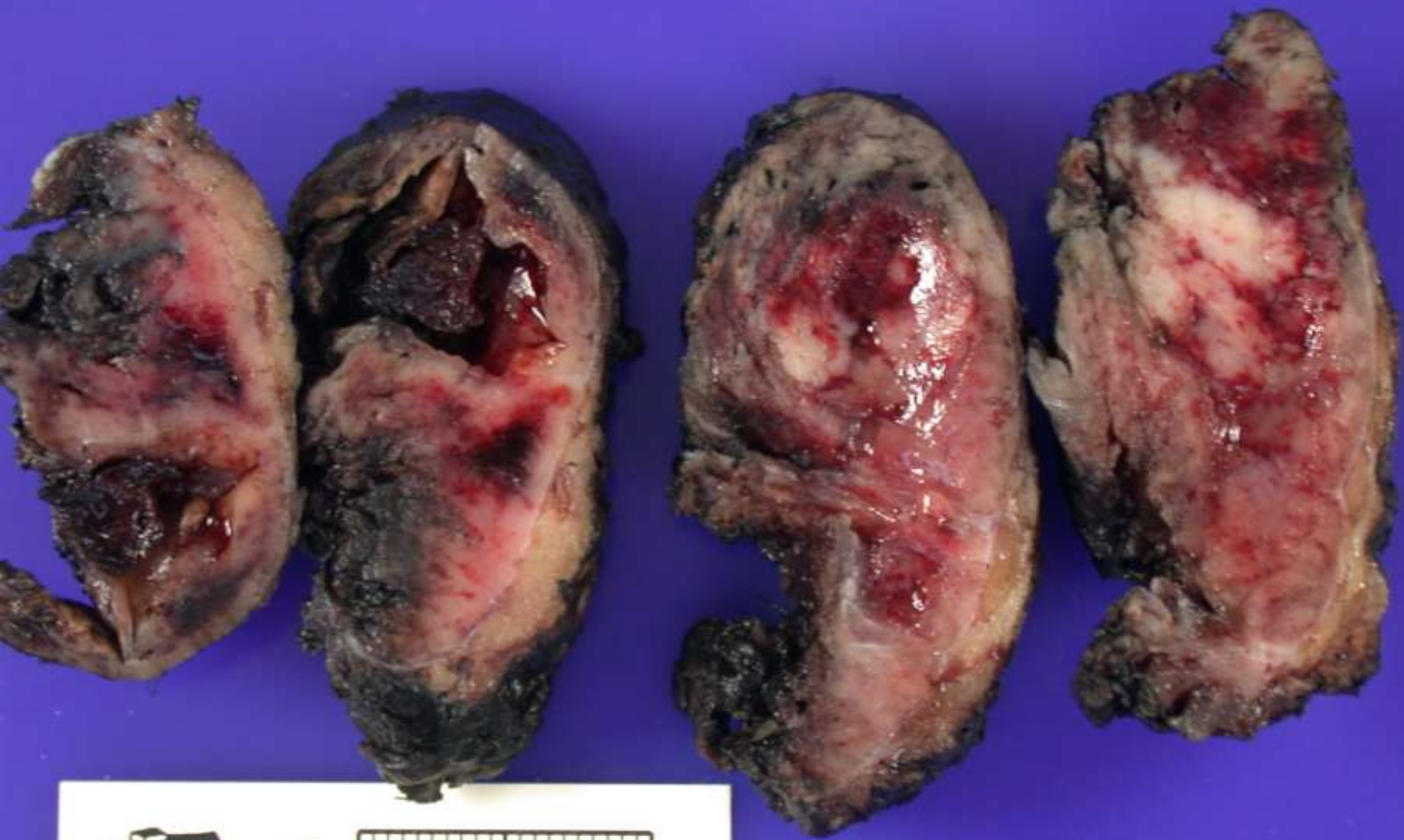B09-01578

H.V.C. - Pamplona - S.º Patología



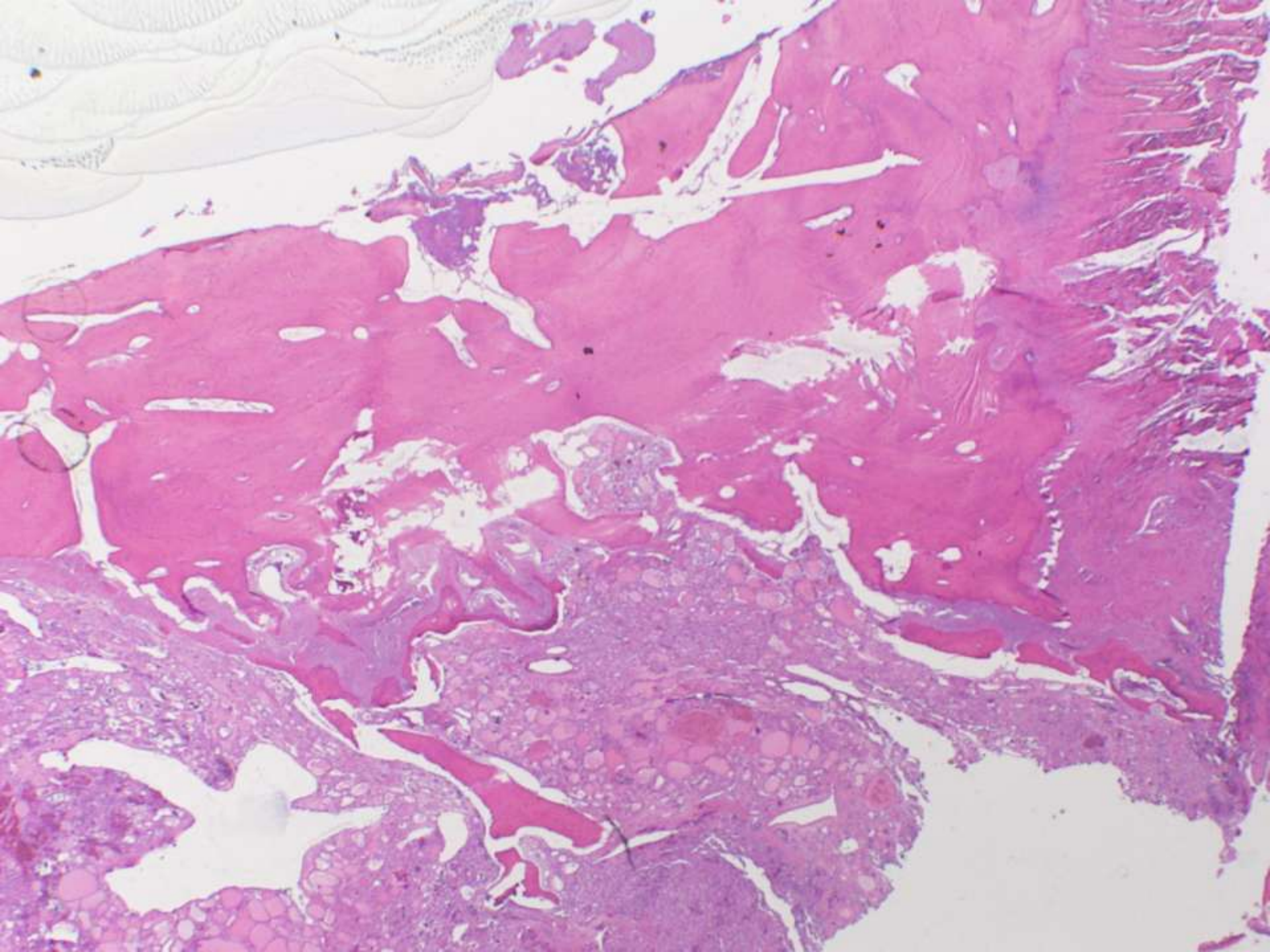
B09-01655

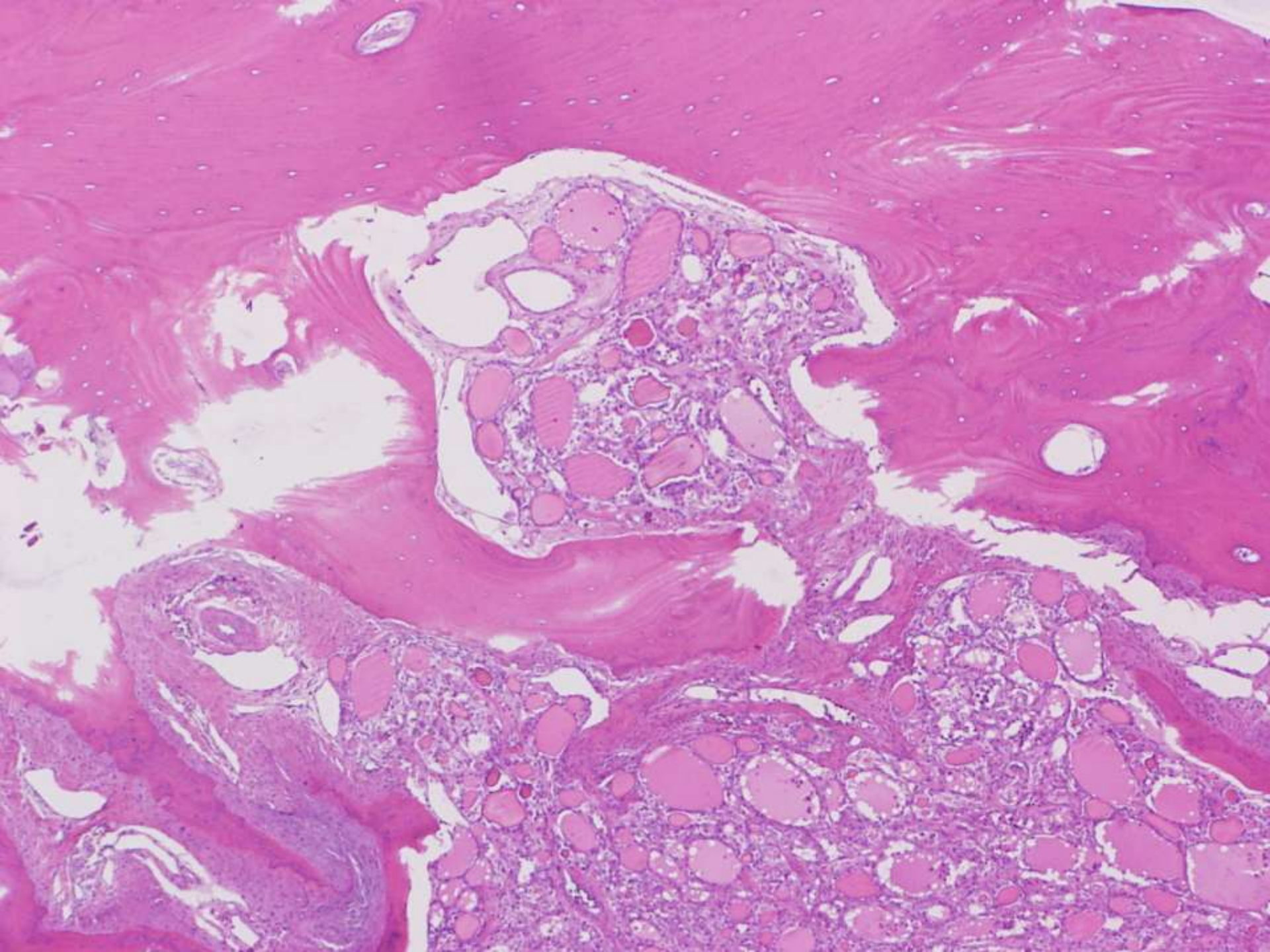
H.V.C. - Pamplona - S.º Patología

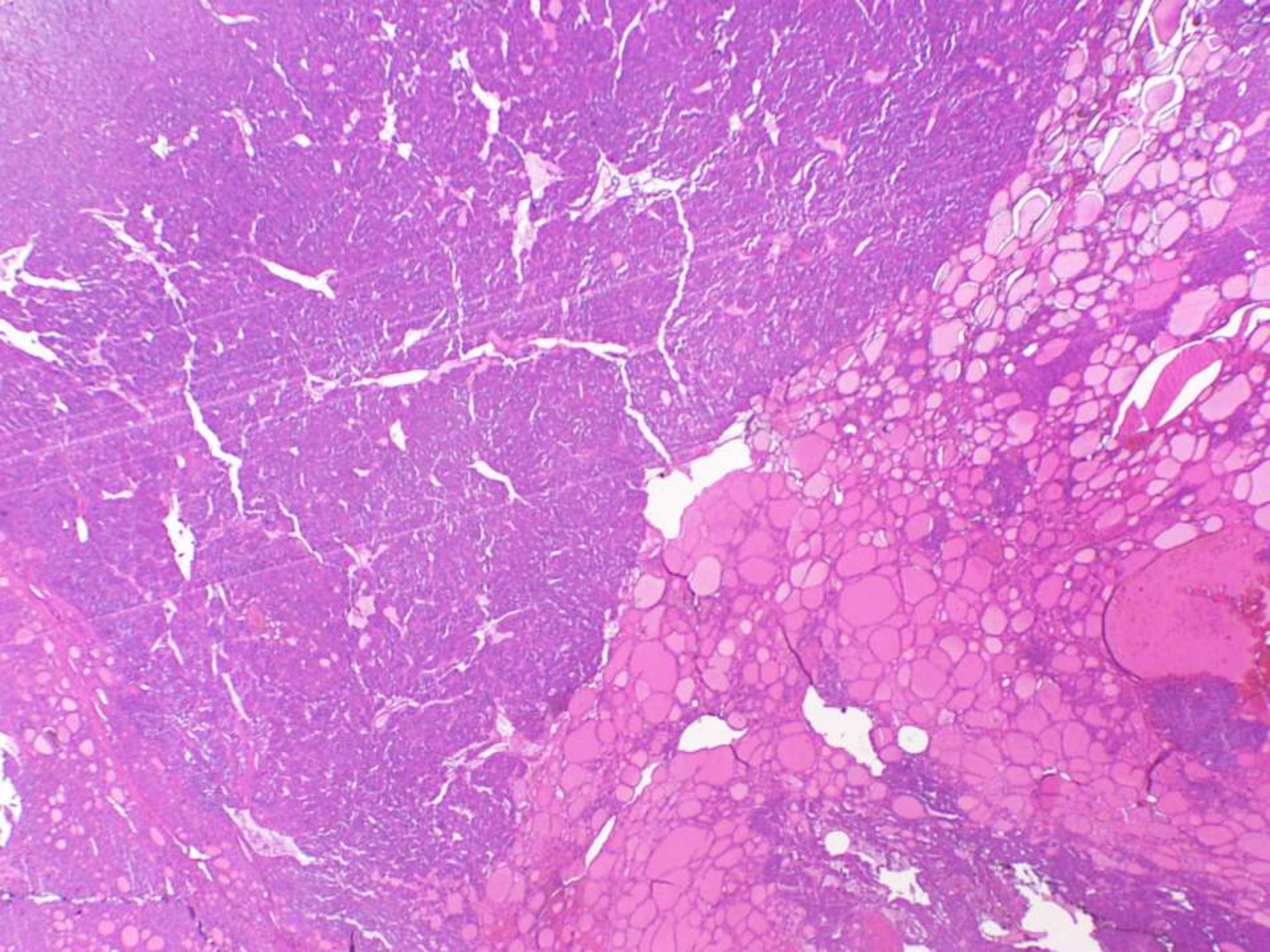


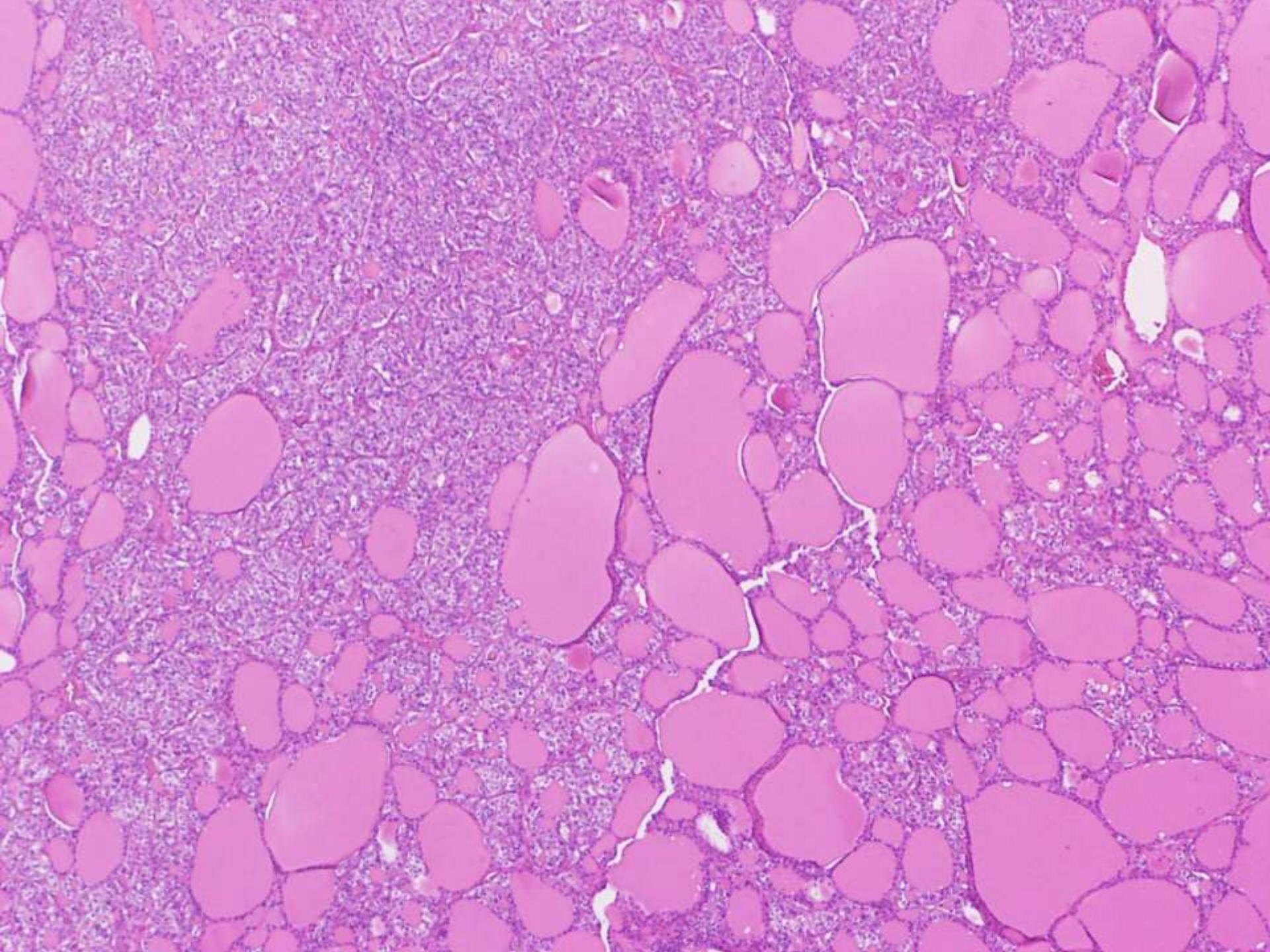
B09-01655

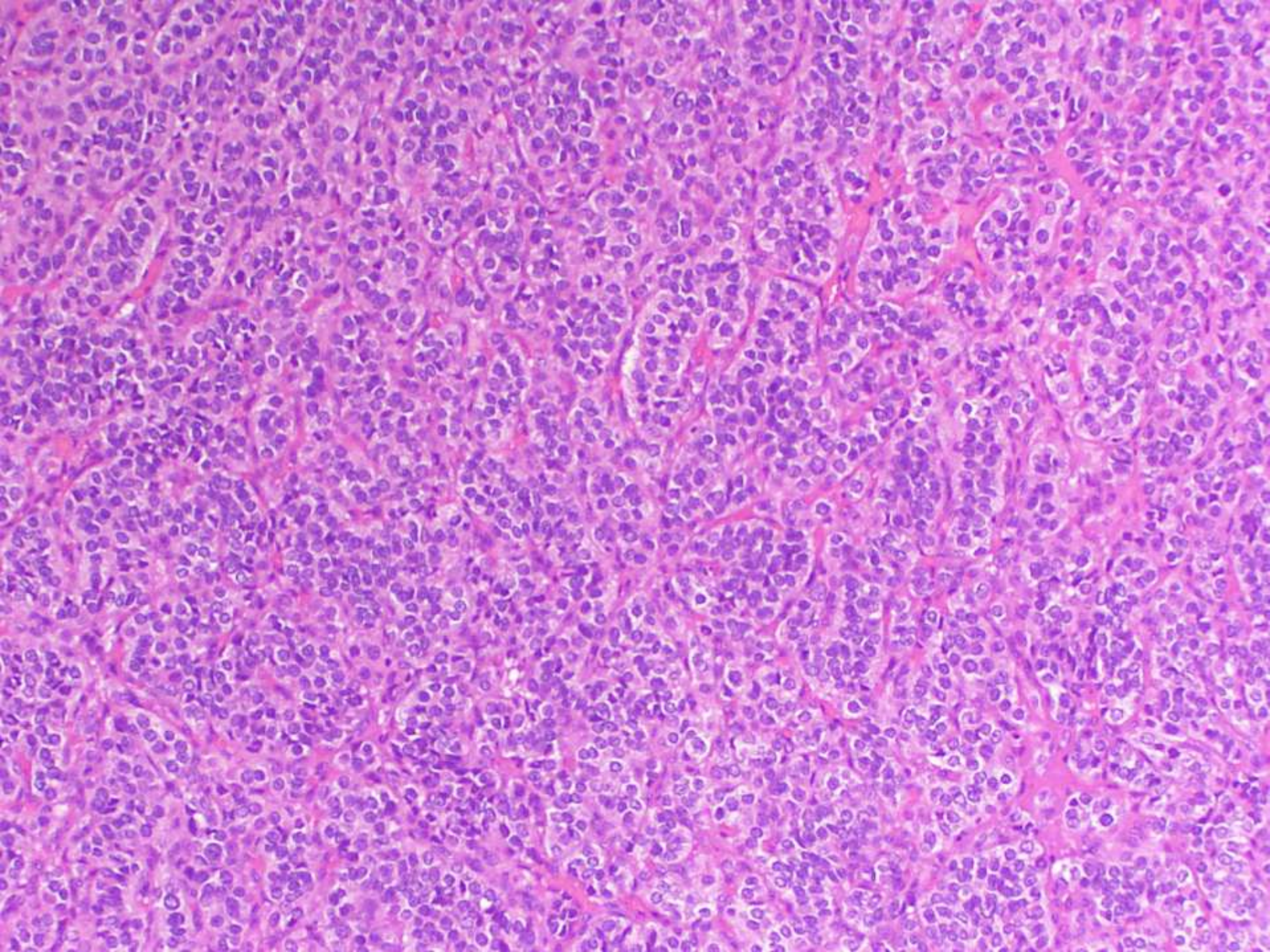
H.V.C. - Pamplona - S.º Patología

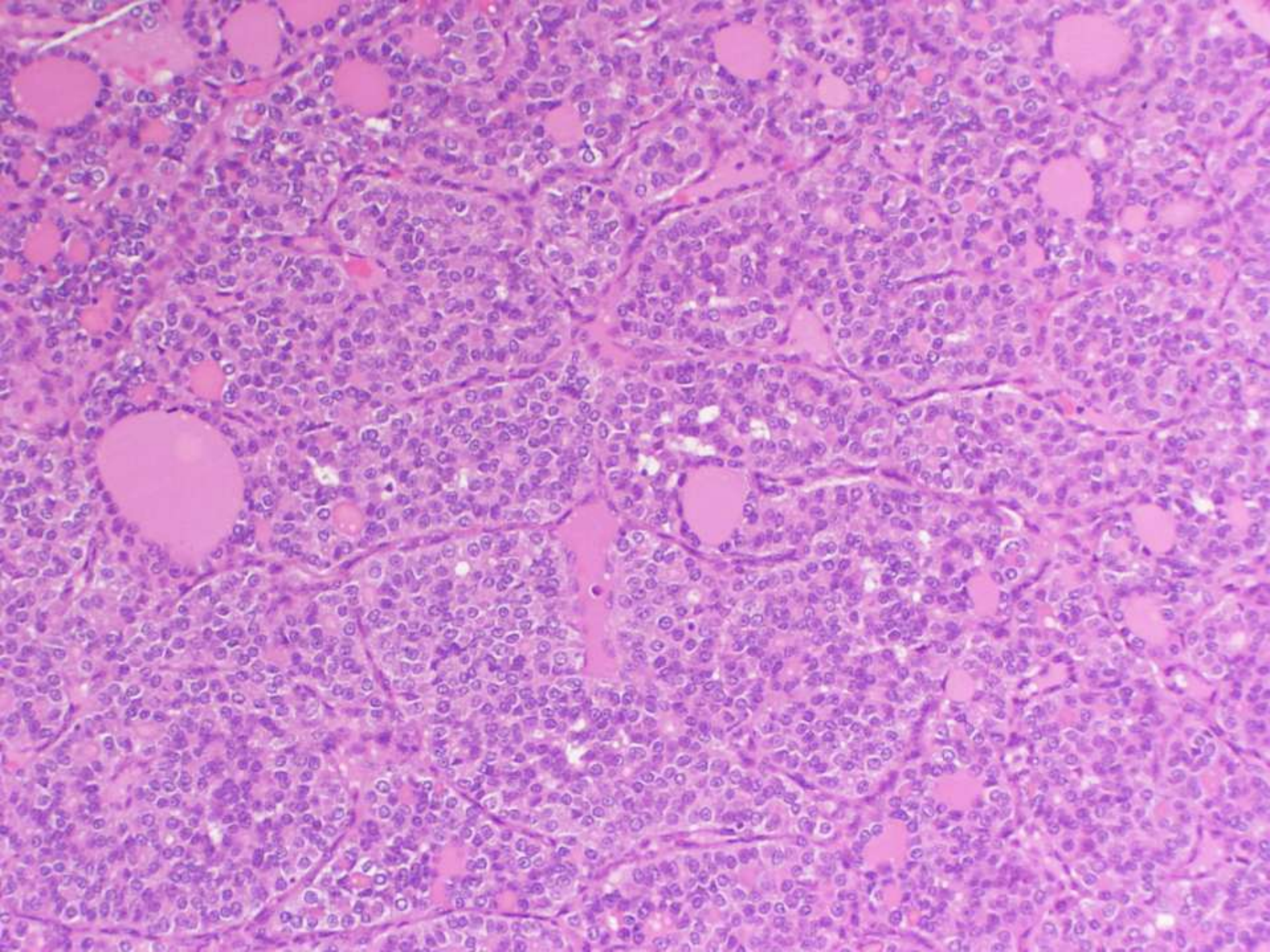


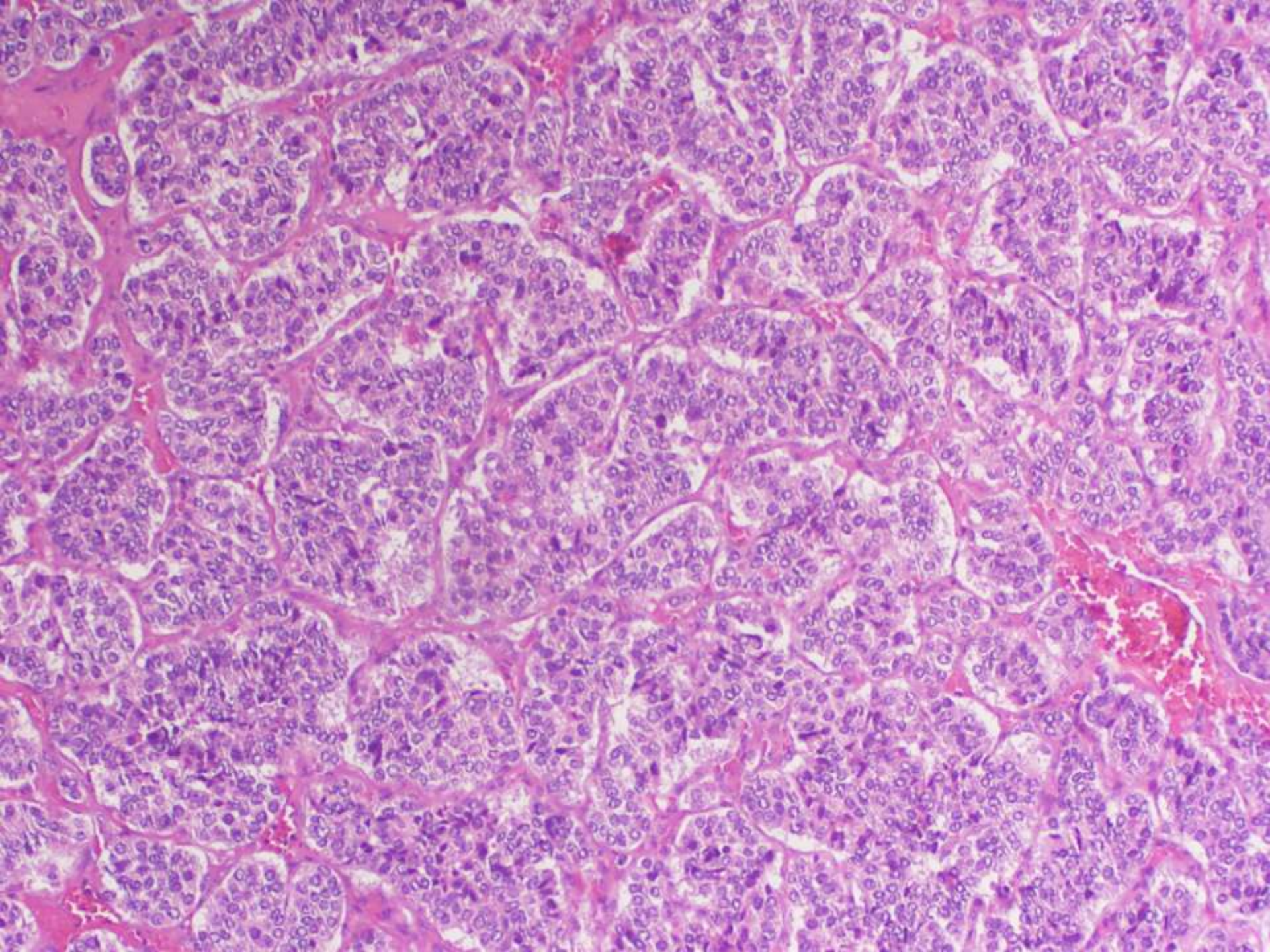


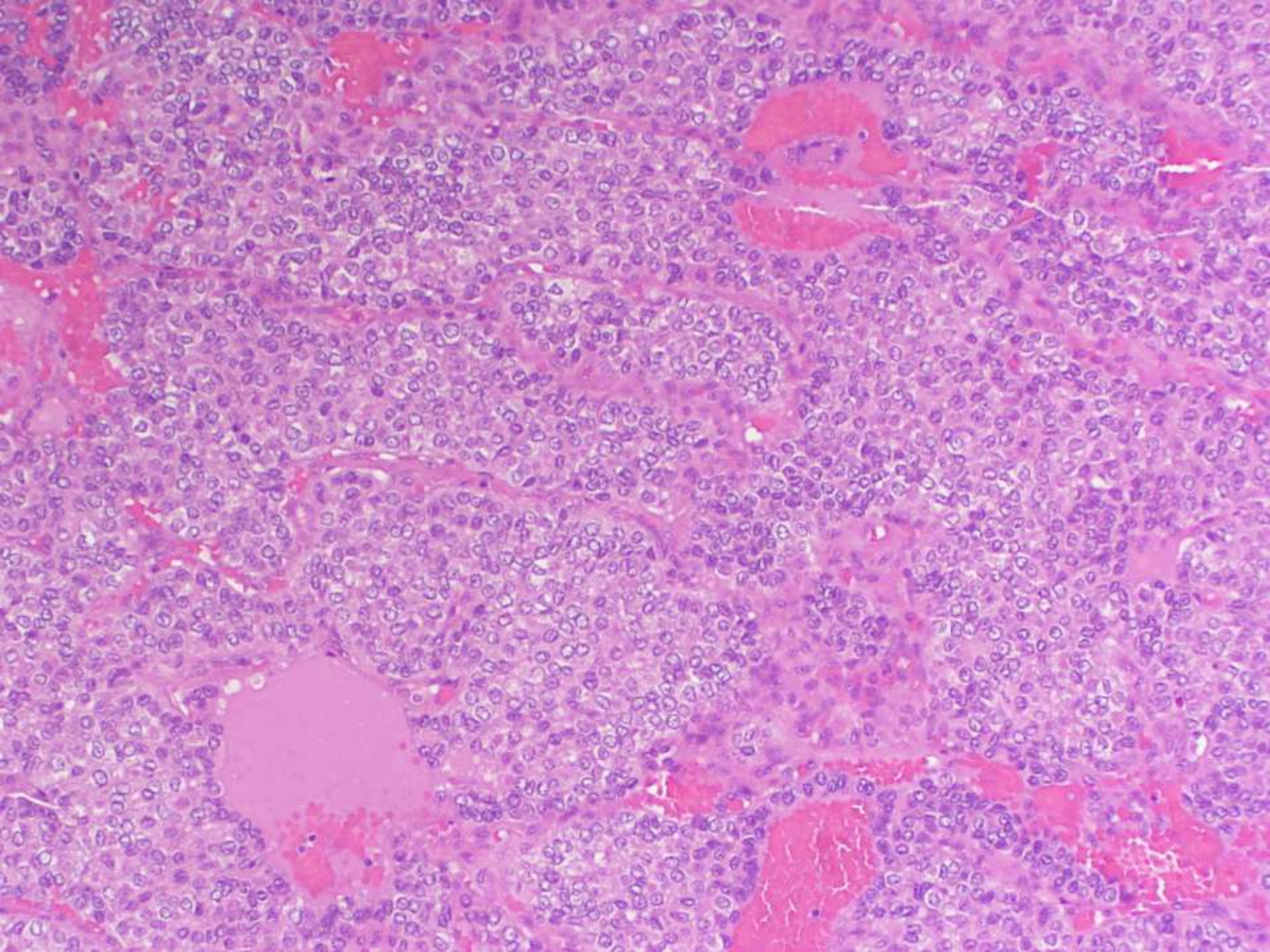


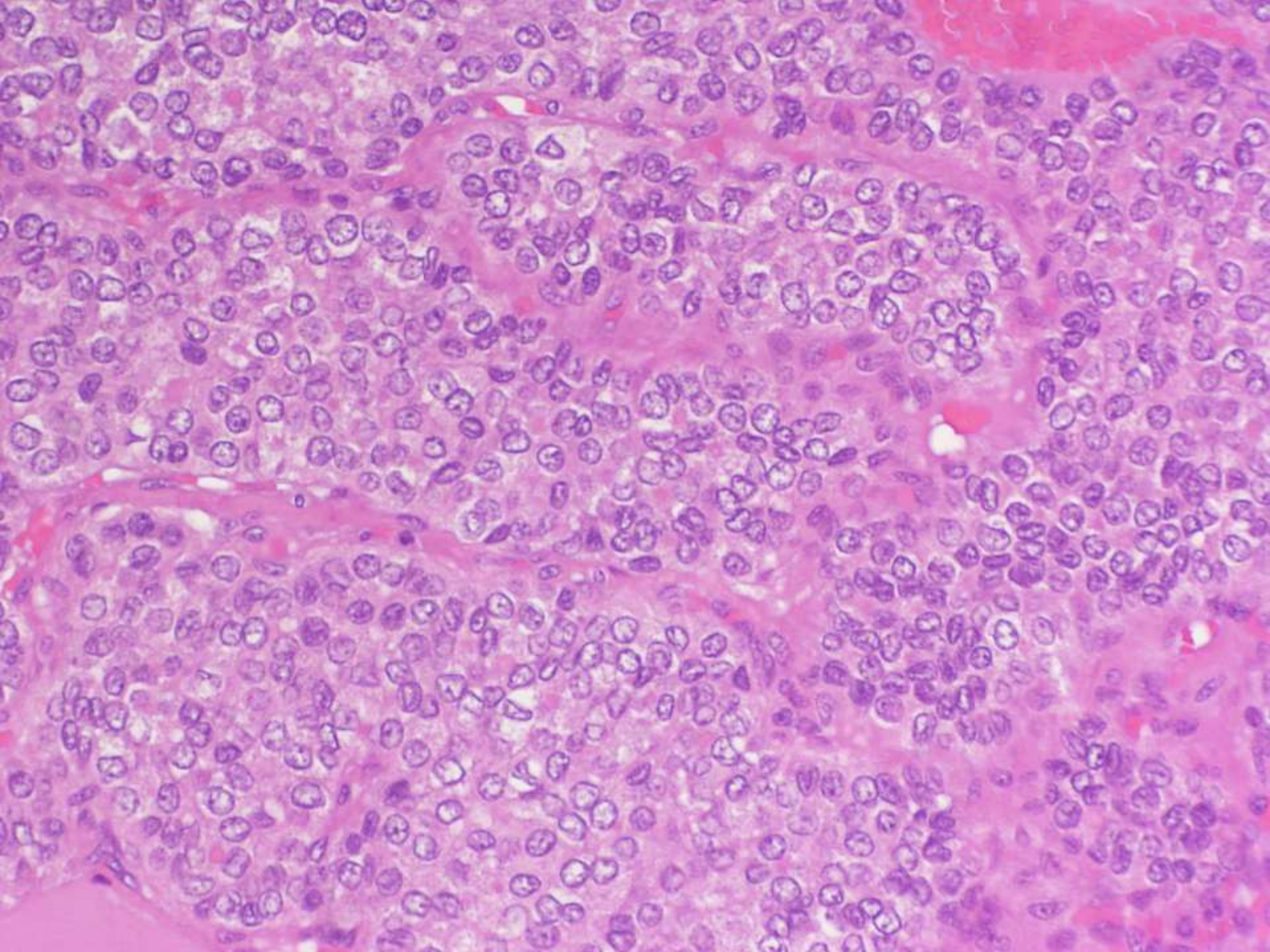


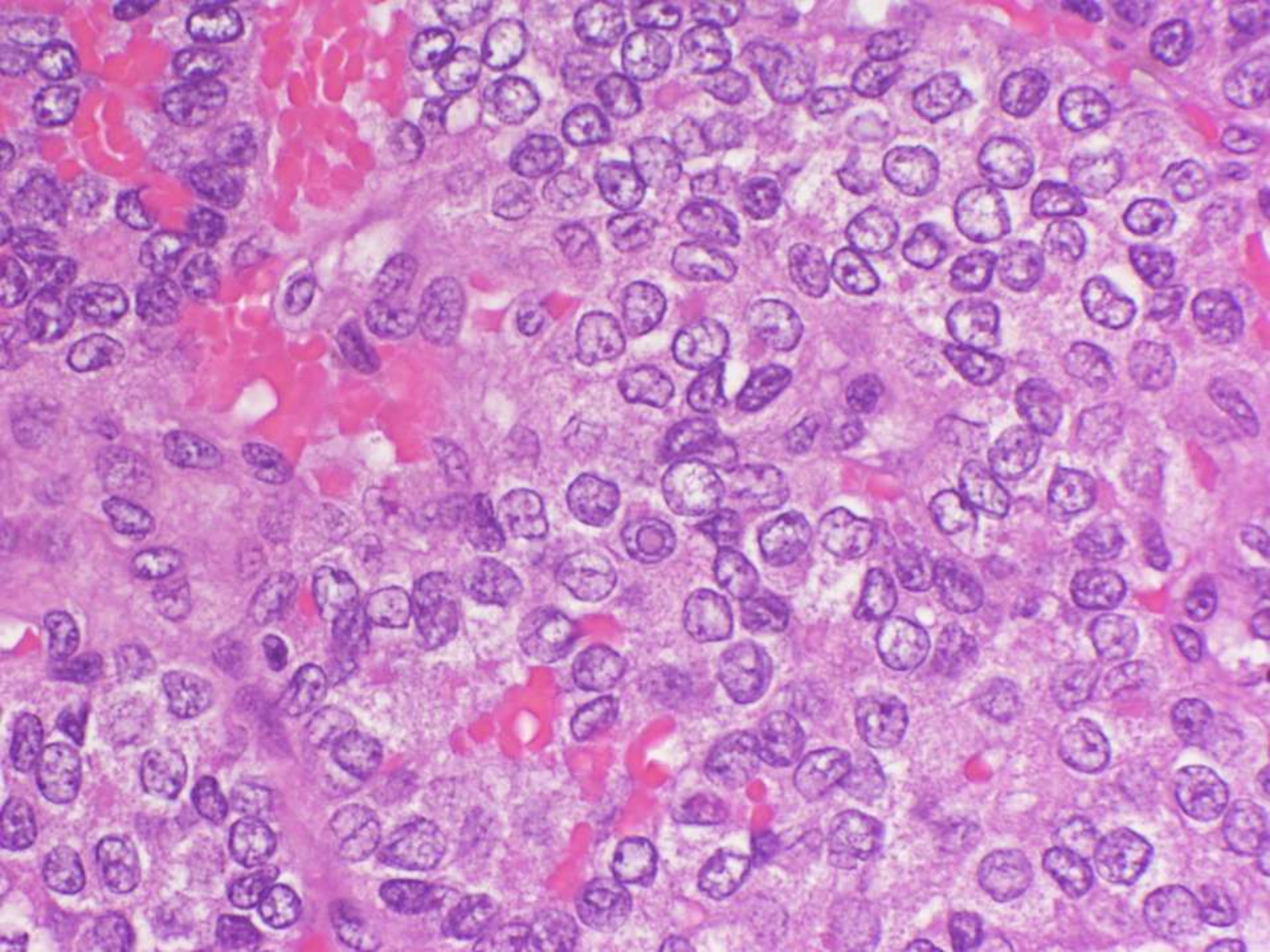


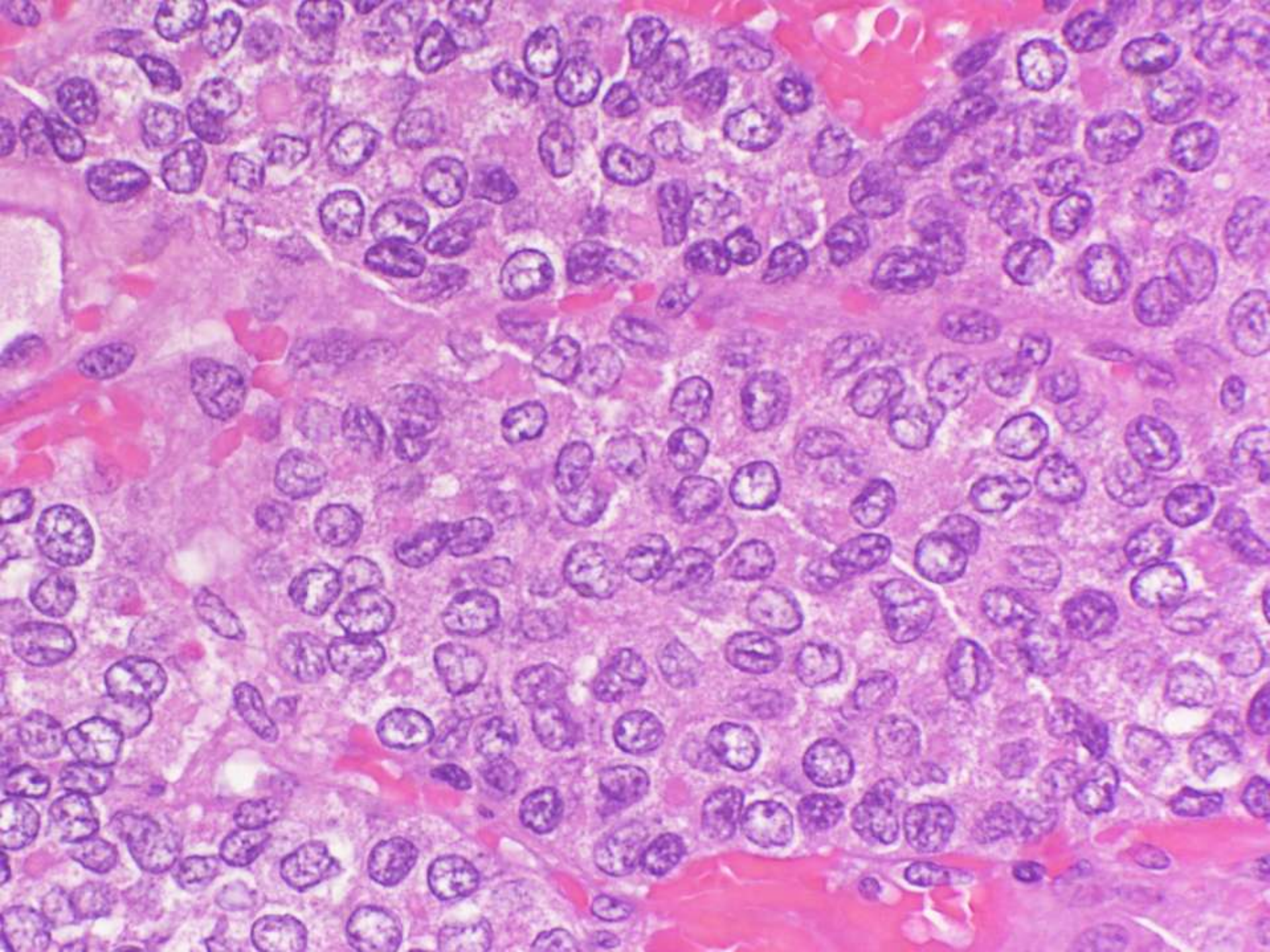


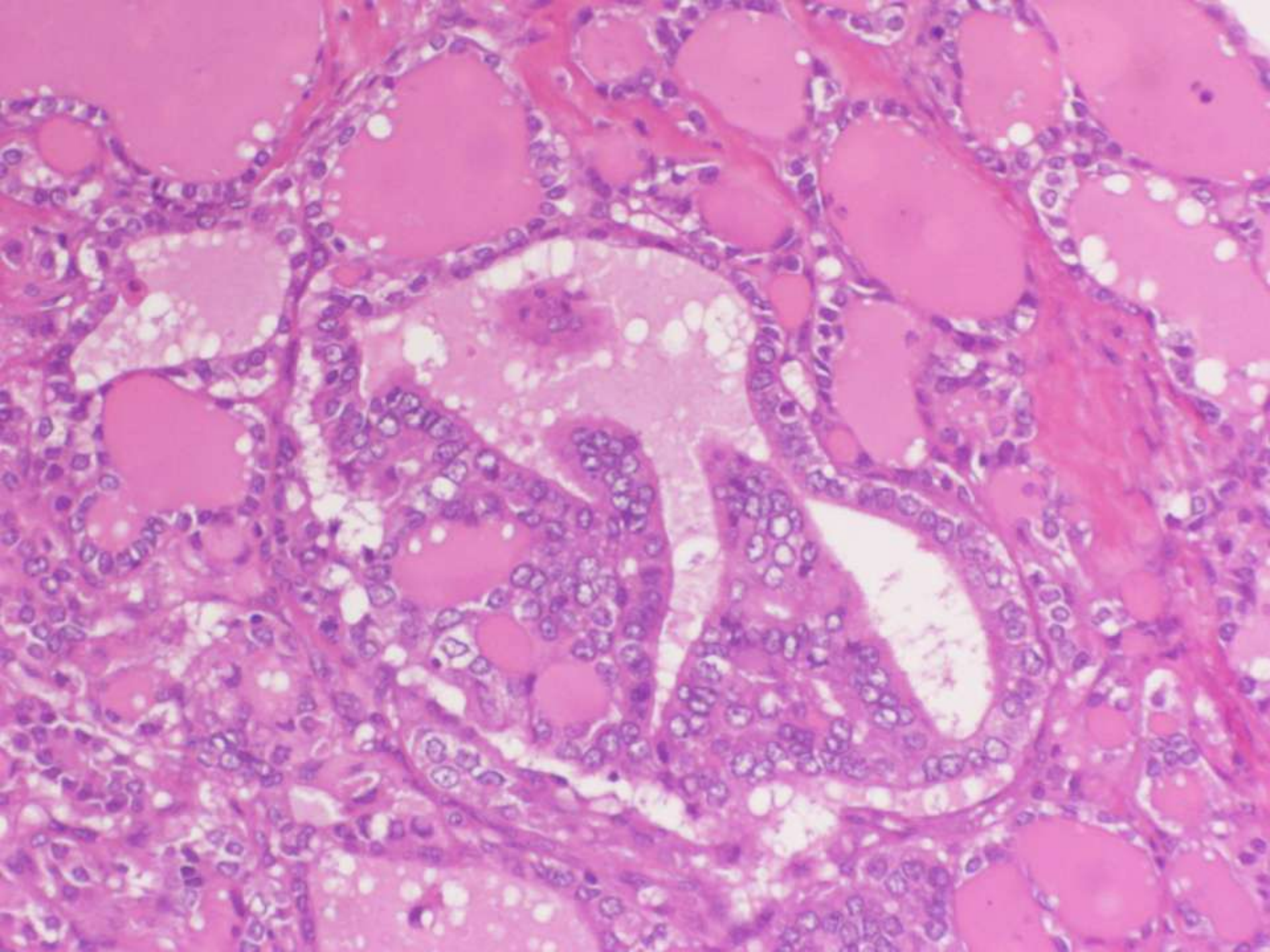


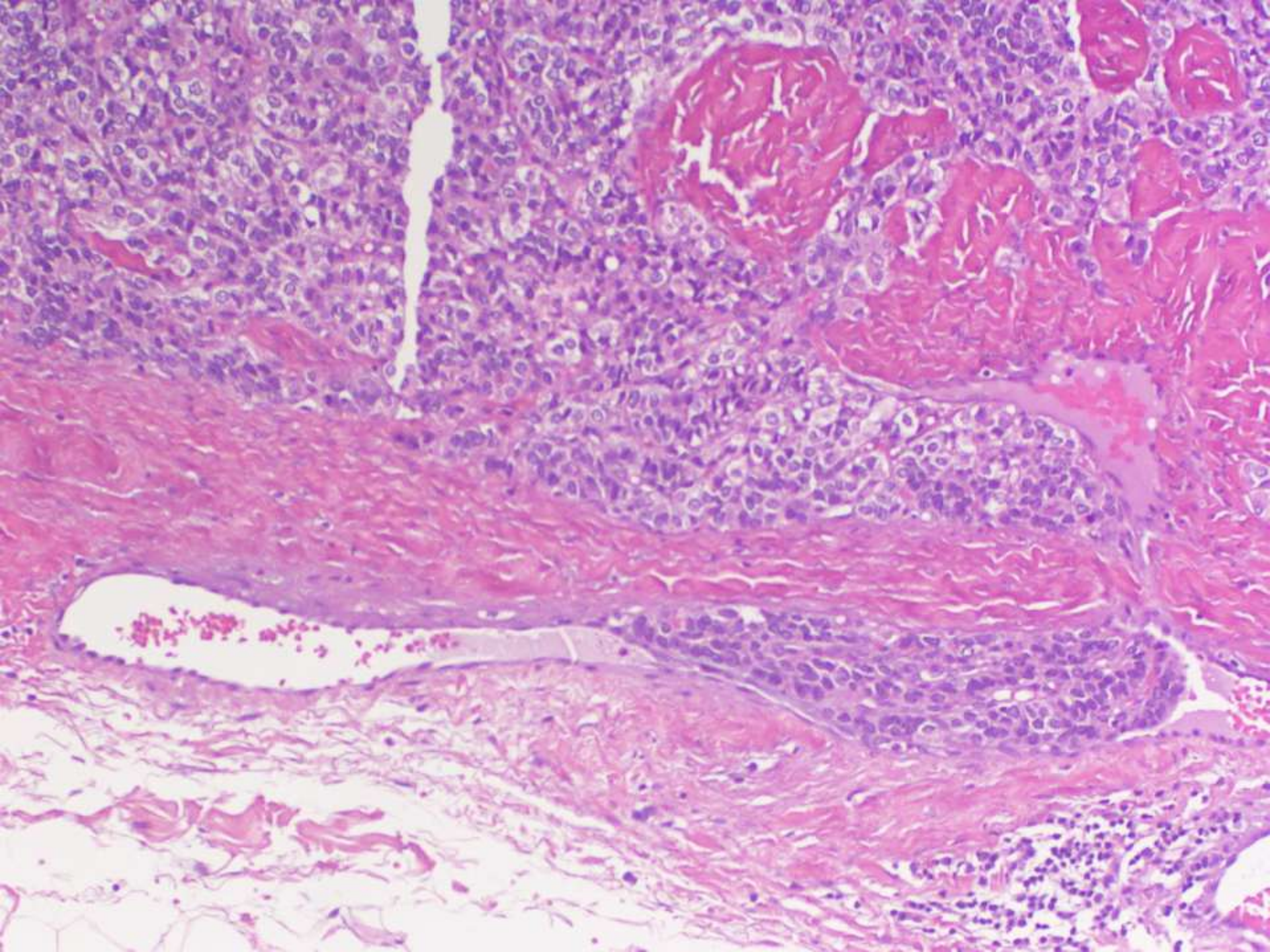












DIAGNOSTICO

METASTASIS MALAR DE UN CARCINOMA DE
CELULAS FOLICULARES DE TIROIDES
POBREMENTE DIFERENCIADO (folicular-
papilar)

TUMORES HIBRIDOS

- Tema muy controvertido.
- Tumores que compartes características clínico-patológicas de carcinoma folicular y papilar.
- Caso: tiroides con un carcinoma folicular mínimamente invasivo con pobremente diferenciado con metástasis ósea única en hueso malar (sin mtx ganglionares ni viscerales) que muestra rasgos citológicos de carcinoma papilar.

TUMOR FOLICULAR ENCAPSULADO

Secciones histológicas:

- Tumor hasta 5 cm: inclusión total de la cápsula.
- Tumor mayor 5 cm: una sección por cm , incluyendo la totalidad de la cápsula de cada sección.
- Interfase tumor-cápsula- parénquima.
- Evitar cortes tangenciales.

TUMOR FOLICULAR ENCAPSULADO

Seriaciones:

- Cápsula fibrosa gruesa.
- Interfase tumor-cápsula irregular con imágenes dudosas de invasión capsular.
- Imágenes no concluyentes de invasión vascular.
- Patrón histológico.

BIBLIOGRAFIA

- Yamashina M. Follicular neoplasms of the Thyroid. Am J Surg Pathol 16(4) 1992.
- Cameselle Teijeiro J., Sobrinho-Simoes M. Carcinoma papilar de la glándula tiroides. Problemas en el diagnóstico y controversias. Revista Española de Patología 36(4). 2003.
- Ackerman LV., Rosai J. Follicular carcinoma. In: Surgical Pathology. 9th ed Mosby 2004.
- Livolsi VA., Asa SL. Thyroid and Parathyroid pathology: a practical diagnostic approach. United States and Canadian Academy of Pathology. 2009